

CHAPTER 1C

STANDARD VAGINAL APPROACH FOR VESICO-VAGINAL FISTULA REPAIR

PRE-OPERATIVE PREPARATION AND CHECKLIST FOR VVF REPAIR

A	Antibiotic prophylaxis is important, preferably with aerobic and anaerobic coverage. A stat dose of: <ul style="list-style-type: none"> ➤ A common regime is gentamycin 6 mg/kg or a cephalosporin plus metronidazole 500 mg IV. ➤ Co-amoxiclav (Augmentin) 1.2 gram IV stat is another option. It is better to reserve one antibiotic that is only used for prophylaxis and rarely for treatment.
B	Blood results
	Bowel preparation before VVF repairs to avoid contamination during surgery. The patient should take only clear fluids for the day before surgery. In addition, there are two options: <ul style="list-style-type: none"> • No enemas are given. The patient is asked to try to defecate the morning before surgery. If there is stool coming after anaesthesia, it is easy to deal with because it is solid. Evacuate it manually, pack the rectum and put a purse string around the anus. • Give an enema the day before surgery. Avoid enemas on the day of surgery as they often work during the operation.
C	Consent for procedure and check details of the procedure.
	Catheter: If possible, urinary catheters should not be used for at least a week before repair to help clear the bladder of infection.
D	Drip: It is a good idea to start intravenous fluids at least 1 hour pre-operatively so that the patient is well hydrated which will make it easier to find the ureters during the operation. Good hydration is also useful for spinal anaesthesia which is used in most cases. <p> Top Tip! It is safer to have two intravenous lines running for every fistula repair. This reduces the risk of hypotension. If this is not possible, at least have a second cannula in place to avoid panic if the BP drops.</p>
E	Equipment: Is any special equipment needed for this procedure? Also, check equipment for monitoring.

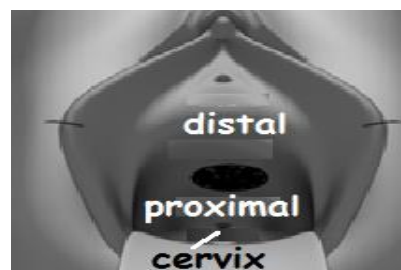
MAIN STEPS OF THE OPERATION

The following steps can be used for the majority of VVFs.

Step 1: Exposure of fistula(s) and ureters, exclude stones, ensure no other fistula is present.
Step 2: Mobilize the bladder and excise scar tissue around the fistula tract i.e. dissect the vagina off the endopelvic fascia and bladder/ urethra.
Step 3: Close the bladder watertight without tension and then do a dye test to confirm closure and then decompress the bladder with a catheter.
Step 4: Consider an intermediate layer.
Step 5: Closure of the vagina and ensure good haemostasis.
Last steps: Pack the vagina and secure the catheters.

The vaginal approach is preferred where possible as it results in lower blood loss, requires simpler anaesthesia, the operative time is shorter and the post-operative recovery is quicker. The indications for an abdominal approach are discussed in chapter 5.

Fig 1.3a: In the following description, the term proximal means the part of the fistula closer to the cervix. The term distal refers to the part of the fistula closer to the urethra.



Tip! Put out the special sutures and catheters that you think you will need before the case so that they are easy to access.

STEP 1: EXPOSURE OF FISTULA AND PROTECTION OF URETERS

In surgery, exposure is everything.


(A) Patient Position: Before scrubbing for surgery, the surgeon must take the time to position the patient properly. It is much easier to do this before, rather than during, the operation. The fistula should be at the

level of the surgeon's eyes (Fig. 1.3b). The exaggerated lithotomy position (Fig. 1.3e) is used and can be achieved by a combination of the following:

- The whole buttocks must be over the edge of the bed with the hips well flexed.
- The patient is placed in a steep Trendelenburg position. This brings the anterior vaginal wall into an oblique rather than a horizontal plane which means it can be seen more comfortably. Shoulder pads are attached to the operating table and placed on the patient's shoulders preventing her from slipping down the table (Fig. 1.3c). These are critical for fistula surgery. However, be careful that there is not too much pressure on the shoulders as this can cause brachial plexus injury. The pads should be just in position to catch the patient if she slips down the table. The head down tilt also has the effect of elevating the end of the bed.

Watch that this position is maintained during the operation or else surgery will become difficult and you may be unaware this is the reason.

 **Tip!** If a fistula is high and difficult, get the buttocks well over the edge and increase the head down.

 **Tip!** If the table has very little head-down tilt or does not elevate sufficiently, try lowering your chair. You may even have to sit on a foot-step so that you are almost on the floor. Alternatively, put 1-2 pillows or a wedge under the patient's buttocks. Another option is to elevate the base of the table with a step or blocks.


 **Tip!** If you have no shoulder pads, you may just elevate the patient's shoulders using a wedge or mattress. This will prevent her from slipping down the bed. Also, get the buttocks well over the end of the bed.

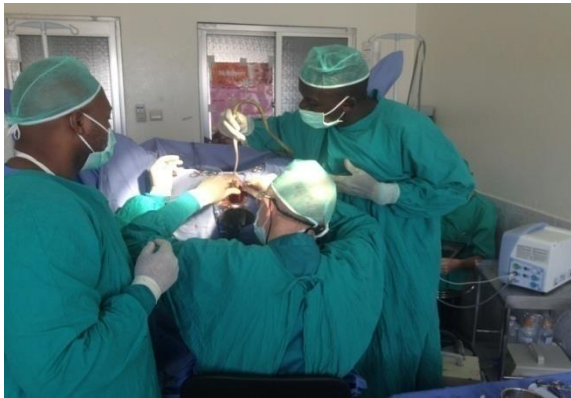

Fig. 1.3b: Shows the fistula at the correct level of the surgeon's eyes.

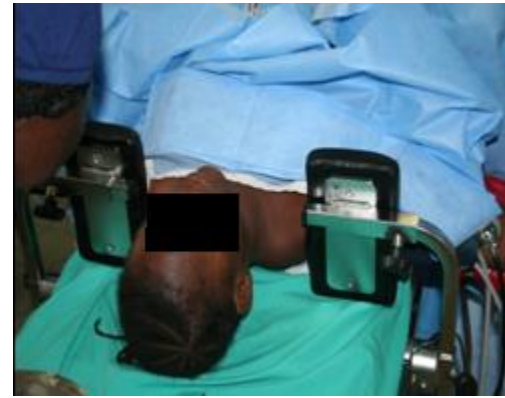


Fig. 1.3c: Shows the shoulder pads in position.

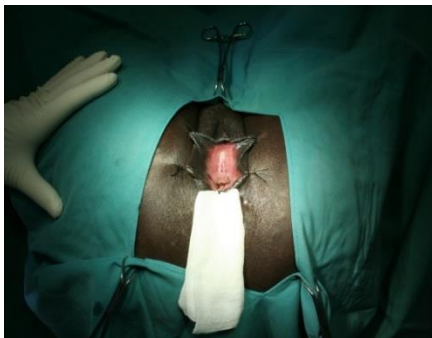

Fig. 1.3d: Shows the labia sutured back and gauze swab in position. A useful trick is to place a continuous suture of 3-4 bites between the vagina and the gauze as this prevents any contamination.

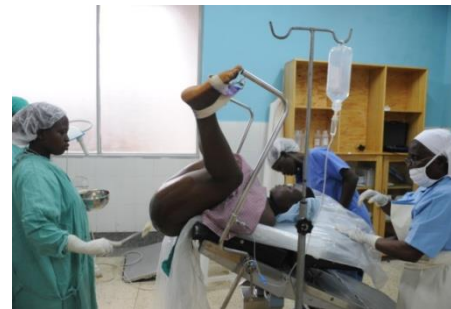

Fig. 1.3e: Shows the exaggerated lithotomy position with the buttocks well over the end of the bed and the hips well flexed and slightly abducted.

 **Tip!** It is a good idea to fix a towel clip over the pubic symphysis in the midline to the skin as seen in Fig. 1.3d. This avoids the drapes slipping down the bed when the patient is put in the Trendelenburg position.

(B) Suturing:

- To improve exposure, stitch the labia minora/ majora back bilaterally (Fig. 1.3d).
- To avoid faecal contamination, put a gauze swab over the anus. If the patient has already soiled or you think she is likely to (stool is seen in rectum), two additional steps are taken before surgery: (i) Pack the rectum with gauze and (ii) Place a purse-string around the anus and place an artery forceps on the

suture end so that you do not forget to remove it at the end of the surgery. The key with this suture is to go deep so that the suture includes the sphincter and not just the skin.

(C) If the vagina is very scarred:

- (a) *Cut scar band:* Often there is a circular ridge of scar on the posterior vagina. This can be cut with a small longitudinal incision on each side at 4-5 o'clock (as shown in Fig. 1.4) and 7-8 o'clock (not shown). If it is incised centrally, the risk of injuring the rectum is high. If necessary, place your finger in the rectum while you make an incision over scar tissue, as the rectum is often closely adherent. After cutting scar tissue, push bluntly with your finger to open up the scarred area.
- (b) *Make an episiotomy:* Most VVFs can be repaired without any episiotomy as episiotomies do not help when the scarring is high up in the vagina. Some surgeons advocate liberal use of episiotomies especially for beginners since good access to the operation field is the first step in any surgery. The episiotomy should be performed at the 5 or 7 o'clock position and not 3 or 9 o'clock position to increase the access.
 - If you have performed a unilateral episiotomy: Any scars in the vagina on the side opposite to the episiotomy can be cut just in the vagina as described.
 - On rare occasions, an episiotomy may have to be performed bilaterally – usually for an RVF repair rather than just a VVF.

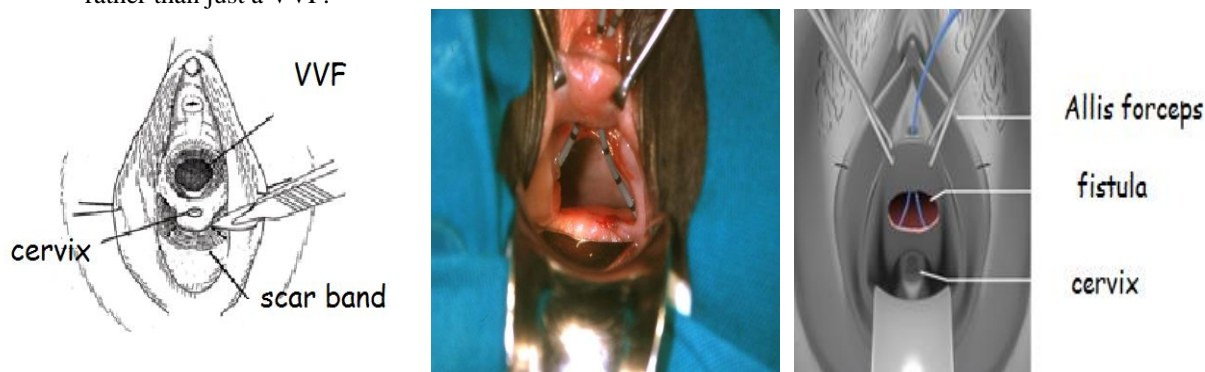


Fig.1.4: Shows the scar band being cut. The scar is represented by the shaded area behind the cervix.

Fig 1.5 a+b: Show the placement of Allis forceps and the speculum to expose the fistula.

! Tip! To expose the scar band, place a retractor on the anterior vaginal wall. Cutting the scar with cautery helps reduce the bleeding. If it still bleeds, it may need suturing later. In absence of diathermy, place a gauze piece soaked in adrenaline 200,000 below the weighted speculum to stop bleeding as you operate.

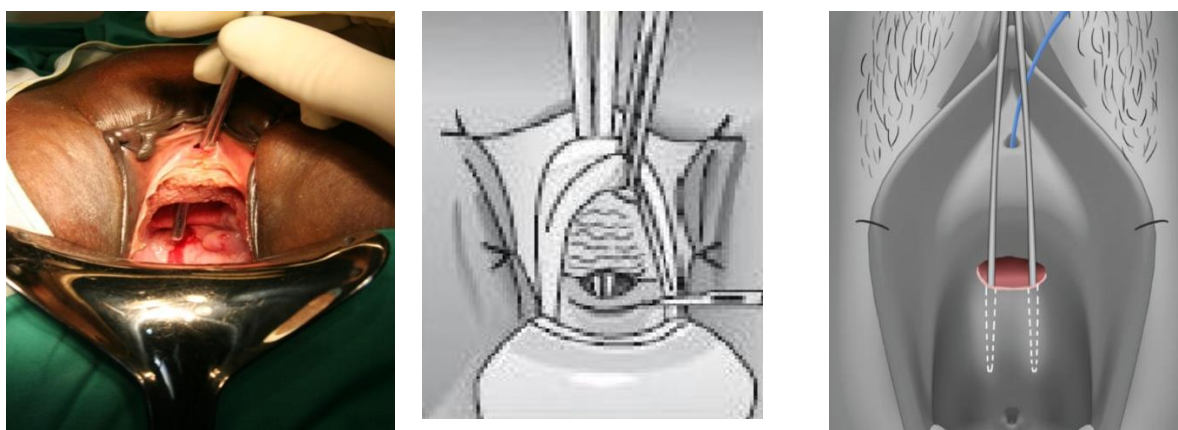


Fig. 1.5c: Shows the metal catheter inserted into the urethra to expose the fistula.

Fig. 1.5d: In this case, an artery forceps (inserted via the urethra) is used to display the edges.

Fig. 1.5e: Shows the vagina being stretched with pickups before making the incision in the vagina.

(D) To expose the fistula:


- (a) Put two Allis forceps distally on the vaginal skin to stretch the opening of the vagina by pulling up and outwards. These are placed on either side just below the urethral opening as in Fig. 1.5a. If the VVF is proximal, the Allis forceps can be placed further into the vagina just distal to the VVF. Alternatively, just put one Allis distal to the fistula to pull it up.
- (b) In most cases, a weighted speculum is used but if the vagina is small or scarred, either use:
 - a small weighted speculum with a short and narrow blade (Aesculap® EL 736R)

- Sims speculum or a small Deaver retractor may be all that can be inserted.



Tip! If a speculum tends to fall out during the operation, either:

- Place a suture across the upper end of the handle of the speculum. Take a bite of the skin on either side of the speculum which will usually be just below the level of the anus.
 - Fix it with part of the drape and a towel clip across the handle.
- (c) Instead of or in addition to using Allis forceps, a metal catheter or even an artery forceps can be used as a retractor in the urethra which helps expose the proximal or distal edges of the fistula (Fig. 1.5 c +d).
- (d) In smaller fistulas, a pickups/ dissecting forceps is a useful way to display the fistula (Fig. 1.5e).

	<p>FIRST CHECKPOINT: BEFORE YOU START OPERATING</p> <p>Insert a metal catheter into the urethra and the bladder to:</p> <ol style="list-style-type: none"> 1. Make sure the urethra is patent and the fistula you see is not just the bladder end of a circumferential defect (see Fig. 2.6). Measure the length of the urethra. If the urethra is blocked, see section 2.3. 2. Feel the inside of the bladder to exclude the presence of any bladder stones (if present, see section 3.5). The presence of pain on pelvic examination or urine that is purulent or has an offensive smell should have alerted you to this pre-operatively. 3. Confirm the site of the fistula and that there is only one fistula. Look for a second fistula proximally (higher up). It is much better to find it before you start operating than waiting for a positive dye test. This will change your whole approach as it is better to start with the proximal fistula. 4. Check for the position of the ureters before making any incisions especially if it is a large fistula. 5. Is the cervix present? If not, remember it may be stuck to the bladder. 6. Measure the length of the bladder from the external urethral meatus to the dome of the bladder. If you subtract the urethral length from this, it will give you the bladder length.
---	--

To measure the length of the urethra:

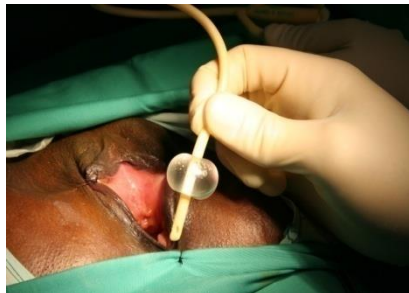
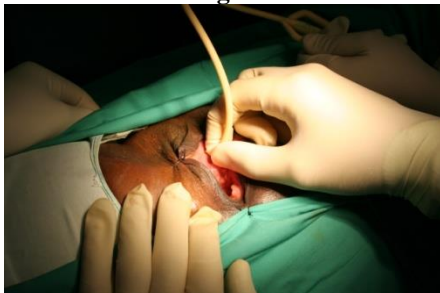
Fig. 1.6 a +b: Measuring urethral length. This is important in assessing the risk of post-repair incontinence (see chapter 6).

- Insert a Foley catheter into the bladder and inflate the balloon with about 3 ml of saline.
- Then pull the catheter back until you feel the resistance of the bladder neck. Then pinch the catheter at the level of the external meatus (Fig. 1.6a).
- Deflate the balloon and withdraw the catheter. Once the catheter is out, re-inflate the balloon with 2-3 ml of fluid and measure the distance from the edge of the balloon to the point pinched off by the operator (Fig. 1.6b). This should be the urethral length.



Tip! If the fistula is very small, pass a probe or uterine sound into the fistula and see if it makes contact with the metal catheter inserted into the bladder via the urethra. This “metal on metal clash or click test” confirms the fistula is into the bladder.


Vaso-constricting agent: This is used routinely to reduce blood loss and improve visibility. Dilution is what makes adrenaline safe to use. Two suggested options for making a solution of adrenaline are to:

- (a) Mix 4 ampoules of 1 ml of adrenaline 1: 1000 in one litre of saline. This gives a concentration of 1: 250,000. You can then use this bag for many cases, drawing up the solution as you need.
- (b) Mix 0.5 ml adrenaline 1: 1000 (measured using a graduated 1ml syringe) to 100 ml saline (measured using the bladder syringe). This gives a concentration of 1: 200,000.

Some add lignocaine to reduce the systemic effects of adrenaline but this is not necessary.

- It takes about 5-7 minutes for adrenaline to start working, 23 minutes to have its maximum effect so you need to inject it early and be patient. It wears off after about 60 minutes.
- If you are doing an episiotomy at 5 or 7 o'clock, infiltrate about 20 ml.

- Infiltrate around the fistula and where you will make the lateral extensions.
- Be sure to aspirate before you inject to avoid injecting into a vessel by mistake. Then only inject as you withdraw the needle.
- It is a good idea to warn the anesthetist and the patient before you inject as she may experience palpitations with tachycardia, headache and elevation of BP. Occasionally the patient gets a compensatory bradycardia in response to the hypertension.
- In the hypertensive patients, it is better to use Normal-Saline without adrenaline for hydro-dissection.

	<p>You have to be very careful with the concentration of adrenaline. A mistake is most likely to happen if someone inexperienced draws it up for you. So always check that it is done correctly.</p>
---	--

LOOKING FOR THE URETERS

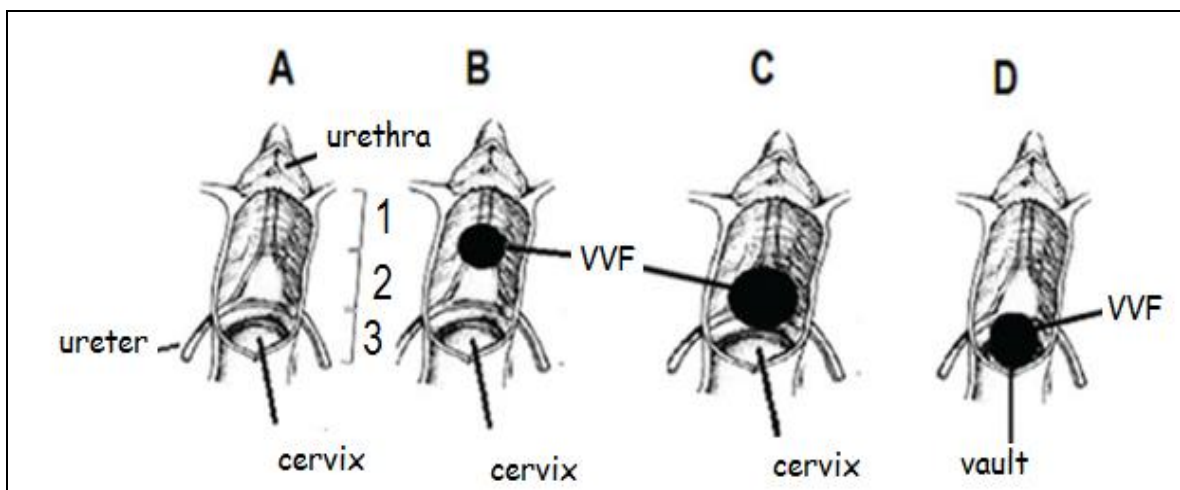


Fig. 1.7a: This shows the anterior wall of the vagina.

(A) This shows the normal anatomy: 1 = distal third of vagina, 2 = middle third, 3 = proximal third.

(B) This shows a mid-vaginal fistula. The ureters are not close to the fistula edges.

(C) This shows a juxta-cervical fistula: The ureters are usually located at 5 and 7 o'clock positions in relation to the fistula opening on the proximal edge as shown here.

(D) In post-hysterectomy and vesico-cervical fistulas, the fistula is located at a higher level above the trigone (i.e. in the upper 1/3rd of the vagina closer to the level of the cervix). In these cases, the ureters open into the distal part of the fistula typically at 10 and 2 o'clock as shown here (see also Fig. 1.7d). As most fistulas are located in the middle or distal third of the vagina (1 and 2 above), the ureters are usually proximal.

Fig. 1.17a adapted from Clinical Urogynaecology 2nd edition 2000. Editors: Stanton S and Monga A; Chapter 23 Genitourinary Fistulae; W Glenn Hurt.

- It is good practice to routinely look for both ureteric orifices. This can be challenging especially if the fistula is small.
- With large fistulas, the intramural part of one or both ureters may have sloughed so the ureteric orifices are found along the edge of the fistula or occasionally they open separately into the vagina.
- With large fistulas, especially those that extend close to the cervix, it is better to catheterize both ureters at the beginning. The closer the fistula is to the cervix, the greater the chance that the ureters will be close to the edge of the fistula. However, do not expect normal anatomy after obstructed labour and you must assume the ureters are in danger for most VVFs.
- In smaller fistulas, visualization of the ureters is not possible (without cystoscopy) until the vagina is mobilized i.e. after step 2 is done.
- If the fistula is juxta-urethral, the ureters are unlikely to be near the edge but always check for them where possible – you will get surprises!

Tips for finding the ureters: there are various ways to see inside the bladder:

- The metal catheter is a useful small retractor. In fact, using the metal catheter and the suction tip at the same time is a useful way to see inside the bladder.

- Another option is to insert a pickups/ dissecting forceps or an Allis forceps into the bladder and spread them open to display the inside of the bladder.
 - Insert one or two Allis forceps on the edge of the fistula to stretch the bladder edge (see Fig. 1.8a).
 - In larger fistulas, insert a Sims or a small retractor into the bladder to retract the distal edge (Fig. 1.7b).
- If you fail to find the ureters after a few minutes, run the intravenous fluids fast and give frusemide 10 mg IV. The increased flow of urine will make it easier to see the ureters by allowing you to see the spurts of urine. In fact, it is a good idea to routinely give frusemide for all VVF cases as you should know where the ureters are.

! Tip! Frusemide only works well and quickly if the patient is well hydrated. It is a good idea to start intravenous fluids at least one hour prior to surgery. This will avoid delays in finding the ureters during surgery.

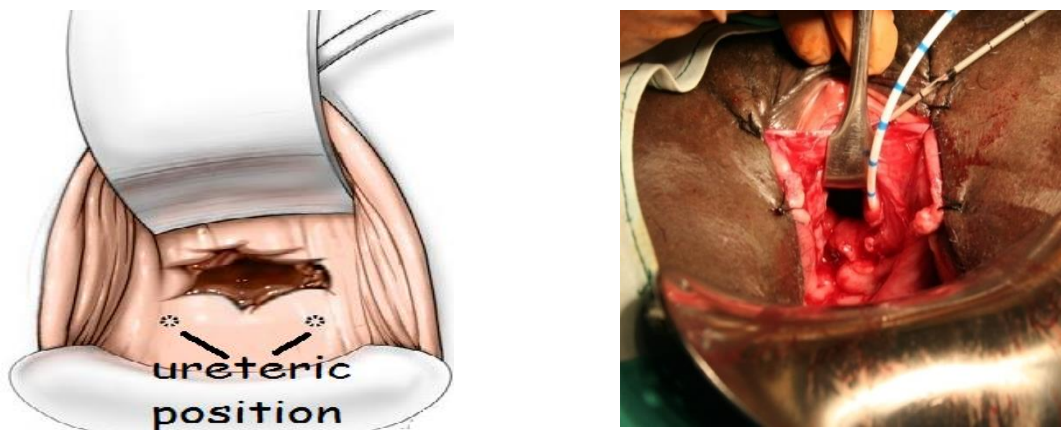


Fig. 1.7b: Diagram on the left (courtesy of Grace Chen) shows where to expect the ureters to be inside the bladder in a mid-vaginal fistula as seen from the vagina. The diagram on the right shows a Langenbeck retractor being used to retract the distal bladder wall so that the ureters can be seen on the proximal wall.

- ◆ If you cannot find a ureter in the bladder, look outside the bladder. If the inside of the bladder seems to be dry despite giving frusemide, look at the area where there is fluid. If you have done some dissection, the “blood” may be diluted by urine so you may not realize that you are mopping up urine with the blood.
- ◆ Do not enlarge the fistula to look for the ureters as you could cut the ureters. However, you may excise scar tissue around the fistula edges which often opens up the fistula and makes it much easier to see the ureters.
- ◆ The position of the cervix can be a guide to the site of the ureters, as each ureter will be on either side of the cervix. This can be very useful in large fistulas that extend out to one side i.e. if the ureter that you have found runs around the left side of the cervix, it is the left ureter.
- ◆ If you fail to find a ureter on one side, a post-operative ultrasound should be done in case there is already a ureteric obstruction/ fistula or in case you have obstructed the ureter during the present surgery. However, it is a good idea to do an ultrasound on all VVF patients pre-operatively to warn you of potential problems.

If the ureter is just inside the bladder (around a corner) but it is difficult to catheterize, the following tips may help:

- (a) Place an Allis forceps above and below on the bladder edges. By stretching these, the ureteric openings may be more visible (see Fig. 1.8a). Dissect the vagina from the bladder before catheterizing. With the bladder more mobile, it will then be easy to catheterize the ureter. Stay close to the vaginal wall to avoid cutting into the ureter.
- (b) Excise any scar tissue in the edges of the bladder as this will make the edges more pliable. It is then easier to see the ureters inside the bladder.

Once you find the ureter: Once the ureteric opening is seen, apply an Allis forceps near the opening (it is usually easiest to apply it just below the orifice as this will pull the bladder mucosa well down). A small metal probe is then used to identify the exact point of the ureteric opening and is passed up the ureter 2-3 cm. The ureteric catheter can be inserted behind the metal probe as the probe is withdrawn.

CAUTION! A metal probe may cause a false tract so never use force if it does not go in without resistance. The direction the ureter runs (as you pass the catheter) tells you which side it belongs to. If it runs to the left, it is the left ureter, if it runs to the right, it is the right.



Avoid applying Allis forceps on the bladder mucosa until you have clearly seen the opening as they can cause tearing and bleeding from the mucosa which will make it more difficult to find the ureteric opening.

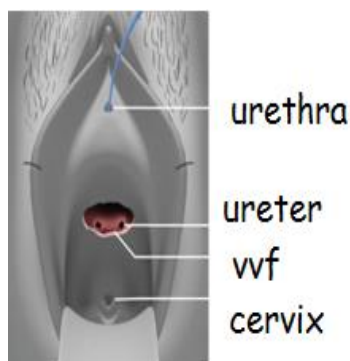


Fig. 1.7c: Shows the ureters in the typical 5 and 7 o'clock position.

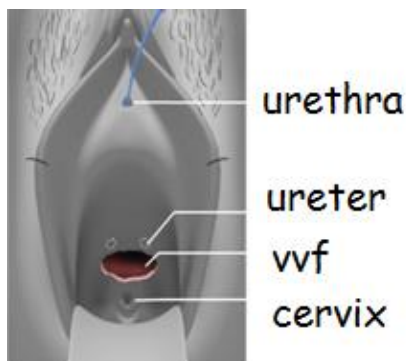


Fig. 1.7d: When the fistula is close to the cervix, the ureters are often at 2 and 10 o'clock.

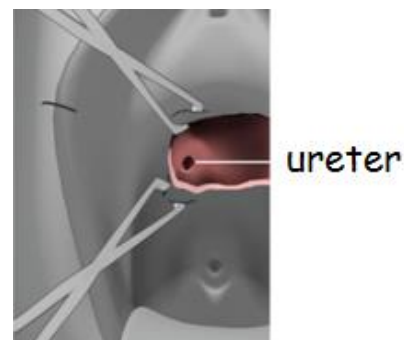


Fig. 1.8a: Shows two Allis forceps stretching the angle of the fistula to demonstrate the ureter.



Tip! Watch out for unilateral or bilateral double ureters. In such cases, you have to deal with 3 or 4 ureters. The incidence of double ureters has been quoted as 1:125. The extra ureter(s) may be found opening into the bladder or vagina. *Reference: Double ureter at repair of obstetric fistula: Kelly J, Moghul F. A, Pisani V. International Journal of Gynecology & Obstetrics. 2008; 102(1):77–78.*

CATHETERIZING THE URETERS

Unless you find the ureters are far away (> 3 cm) from the fistula edge, it is necessary to catheterize them. This is to avoid injuring or ligating the ureters during the repair. A size 5 or 6 ureteric catheter is inserted into each ureter as far up as it will go (usually about 20 cm – the ureteric catheters are usually labelled in centimeters). The other ends of the catheters are then drawn out through the urethra either by:

- (a) Threading the ureteric catheter into the lumen of the metal catheter (which has been passed into the urethra) and then pulling the metal catheter out (see Fig. 1.8b). To do this, it is necessary to take the wire out if present in the catheter. Hold the catheter with the non-toothed dissecting forceps as you push it up the lumen of the metal catheter. This will not damage the catheter.
- (b) Inserting curved mosquito forceps through the urethra, catching the catheter and pulling it out (see Fig. 1.8c).

Sometimes it is better to leave the wire in situ in the catheter. This makes the catheter easier to feel and partially protects the ureter in case the catheter is cut accidentally. This is because if a wire is in the catheter, you can usually only cut one side of the catheter and ureter as you cannot cut through the wire unless you use very sharp and strong scissors. To keep the wire in place, the options are:

1. Do the dissection with the wire in situ before you pull the catheter through the urethra. This is the best option.
2. Remove the wire, pull the catheter through and then the wire can be put back in once the catheter is pulled through the urethra although it is not always easy to do so.
3. Pass the catheter with the wire in situ first into the urethra. You can then pick it up in the bladder with forceps. The catheter is then passed up the ureter. This makes it easier to keep the wire inside.

If the catheter (or the metal probe) will not go up the ureter or if you have trouble getting into the ureter, try the following steps (this assumes that urine is seen coming from the orifice i.e. the ureter is unlikely to be completely blocked from any previous surgery):

1. Apply Allis forceps close to the orifice and pull gently to straighten out the ureter. It is usually best to apply the Allis just proximal (below) to the ureteric orifice and then pull upwards.
2. Pull the wire (if present) in the ureteric catheter back a few centimeters. This may help the catheter go up more easily.
3. Try a smaller size catheter e.g. size 4F.
4. If the catheter will still not pass up, it may be necessary to mobilize the vagina off the bladder (see Step 2 below) first and then try again.
5. Try to pass a small metal probe up carefully. This may straighten the ureter. Then with the probe in place, pass the ureteric catheter up beside this as you withdraw the probe. Alternatively, try a guide wire and pass the catheter over this.
6. If you are only able to get the metal probe in, then do the dissection with the probe in before trying to insert the ureteric catheter. The main reason the probe or catheter does not run up the ureter is the direction you are trying to push it.

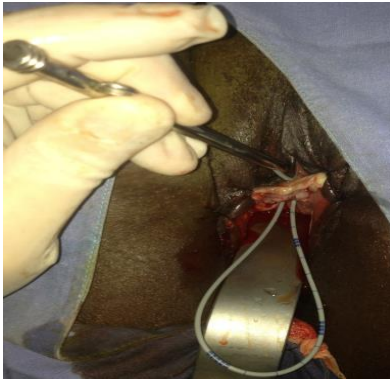

Fig. 1.8b:
Shows the ureteric catheter being pulled through the urethra with a metal catheter.

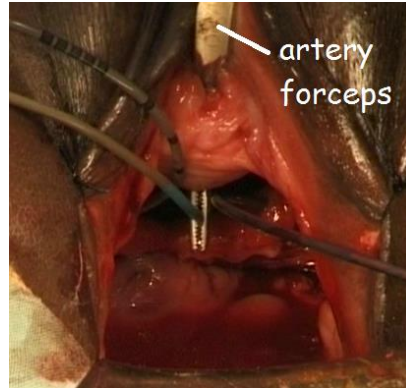
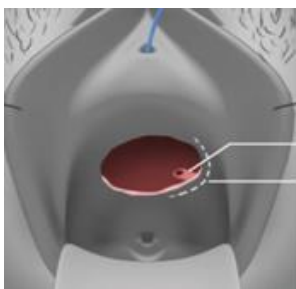


Fig. 1.8c:
Shows the ureteric catheter being pulled through with artery forceps.

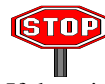

Fix the catheters carefully to the suprapubic skin as it is easy for catheters to get pulled out after surgery. Stitch the left ureter to the left side and the right to the right side for later identification. Fixation can be done more carefully at the end of the operation (page 33).



ureter
dissection

Fig. 1.9:
Dissection of the vagina off the bladder near the ureteric orifice may help mobilize the ureter and allow the ureteric catheter to pass.



If there is resistance as you push up the ureteric catheter, it usually means that you are creating a false passage. If the catheter is in the ureter, it should go in without resistance. Therefore, to push the catheter up, only hold it with your fingers or non-toothed dissecting forceps. Do not use force or else you can create a false passage.

If you are worried that you may have perforated the ureter i.e. no urine comes when the catheter is in place, flush it. Then remove the syringe and needle you have used to flush the catheter with and watch to see if the fluid comes back down the catheter:

- If the fluid comes back, it means perforation is unlikely although it is possible that the catheter is in a tight false passage.
- If it does not, perforation is likely as the fluid is leaking out at the site of perforation.

If the catheter will not pass despite all attempts and urine is seen coming out of the ureter: In this situation, the bladder stitches have to be placed quite superficially to avoid catching the ureter. It is safer to take several superficial bites rather than one deep bite if you think you are near the ureters. Try to bite only the fascia over the bladder rather than the bladder itself.

- As you do this, check that urine is still coming after each stitch. If it is not, take out the last stitch and re-do it.
- You may obtain a post-operative renal ultrasound to check for any obstruction.

If proper ureteric catheters are not available:

- (a) Use size 5-8 infant feeding tubes. Pass it first into the urethra so that you will keep the large connecting part outside. Once passed up the ureter, stitch the feeding tube to the bladder mucosa with absorbable (preferably plain catgut) suture near the ureteric opening to avoid expulsion by peristalsis. However, be careful not to go too close to the ureteric opening in case the suture obstructs it.



Tip! If you must use feeding tubes, pass them into the urethra and bladder using the metal (urethral) catheter which acts like an (external) introducer. This allows you to manipulate the feeding tube to where you want it to go. This is especially useful when passing the second tube as it can be difficult to know which is the first or the second if you do not have it attached to a metal catheter.

- (b) A less satisfactory alternative is to use the metal probe which is kept in the ureter while mobilizing the bladder and inserting the angle stitches (see step 3 below). You sometimes have to do this if the ureteric catheter does not go up the ureter. The probe is only kept in place until the angle stitches have been inserted and nothing is left in the ureters post-operatively.

STEP 2: DISSECTION OF VAGINA OFF THE FASCIA AND BLADDER

INITIAL INCISION

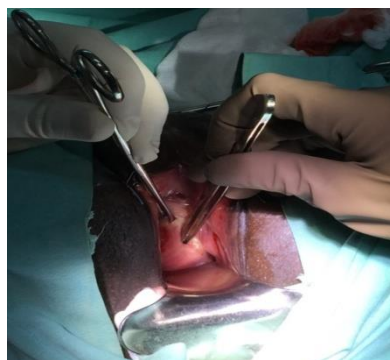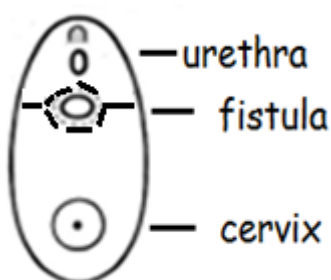


Fig.1.10b: In smaller fistulas, the edges can be stretched by inserting the toothed-dissecting forceps (pickups) into the fistula and opening them to aid making the initial incision.

Fig. 1.10 a: Show the initial incision around the fistula. The lateral extensions vary in length depending on the size of the fistula. When making the lateral extensions, incise at 3 and 9 o'clock i.e. just go horizontally from the lateral angles. This allows for good flaps to close the vagina.

The exact order you make the incisions (as opposed to dissection) is not critical. Usually, I would make the lateral, then the distal followed by the proximal incision.

- Make lateral extensions as shown in Fig. 1.10a to mobilize the vagina. The more mobility you require, the more lateral these incisions should go. In large fistulas, these will extend out from the vagina almost onto the perineal skin. This allows a distal flap (toward the urethral meatus) to be developed as shown in Fig. 1.12 below. In small fistulas, these extensions will remain within the vagina.
- Make a circumferential incision around the fistula edge. Either:
 - try to incise at the junction of the two epithelia (bladder/ vagina) or
 - incise about 0.5 cm from the fistula edge leaving a small rim of vagina on the bladder (see Fig. 1.10 a + b).

Tip! When making the initial incision, only go deep enough to cut the vaginal epithelium, and not the bladder or the pubo-cervical fascia underneath.

DISSECTING THE VAGINA OFF THE FASCIA AND BLADDER

Dissect the vagina off the bladder for about 2 cm all around the fistula. Wide dissection is the key to successful fistula repair in order to allow good mobility of the bladder edges, as these edges must be able to come together without tension. Therefore the larger the defect, the more extensive the mobilization has to be. Tension during closure results in failure. You should have a routine order for dissection of all fistulas as this helps especially with difficult ones (see Fig. 1.10c):

- *Distal:* Do the distal part first for three reasons:
 - It frees up your assistant from retracting.
 - It allows time for frusemide to work.
 - Most importantly as you retract the distal vagina with stay sutures (Fig. 1.12b), it helps expose the proximal part of the fistula.
 Provided you use a vasoconstrictor, bleeding inhibiting your view should not be a problem.
- *Proximal* is usually done next.
- *Lateral:* Lastly dissect the lateral part by opening the para-vesical space if necessary. This is not to be confused with the lateral extensions that are made to reflect the distal vagina.

DISTAL DISSECTION

- This part can be the least accessible. The trick for dissecting is to mobilize the tissue laterally before doing the central part i.e. start laterally and work in towards the centre.
- Hold the vaginal skin with an Allis forceps (point marked X in Fig. 1.11a) in the angle formed by the lateral extension and the distal incision. Then with scissors facing laterally towards the patient's shoulder, cut under the vagina (pulled up by the forceps as in Fig. 1.11b).
- Once this is freed, the part of the vagina over the distal fistula edge centrally is much easier to free (Fig. 1.12a).

- A useful tip, once the dissection is finished, is to stitch the distal vaginal skin flap to the labia majora skin. This keeps the vaginal skin out of the way and helps expose the bladder/ urethra. Put one stitch on each side. Avoid stitching to the labia minora as this will not provide sufficient retraction (Fig. 1.12b).
- The key to getting the distal flap to fold back is to make the lateral extensions lateral enough as shown in Fig. 1.10a.
- Thorek scissors are particularly good for the distal dissection because of their right-angled tips.

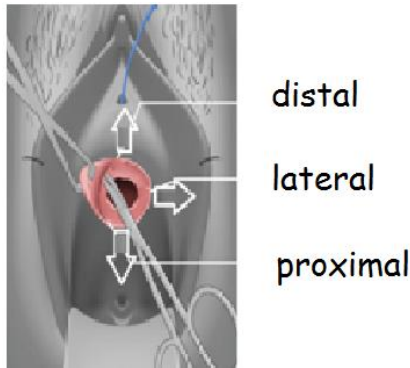


Fig. 1.10c: Shows the areas for dissection: distal, proximal and lateral.

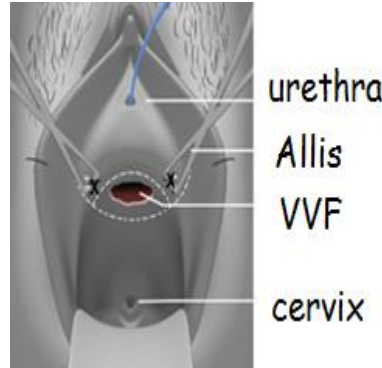


Fig. 1.11a: Shows the area X being held with Allis forceps. The X area is formed by the junction of the distal and lateral incisions.

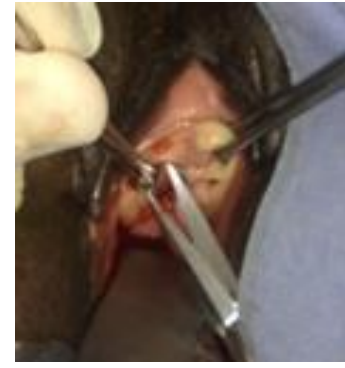

Fig. 1.11b: Shows the scissors aiming towards the right shoulder and about to be inserted under the tissue grasped by the Allis forceps.

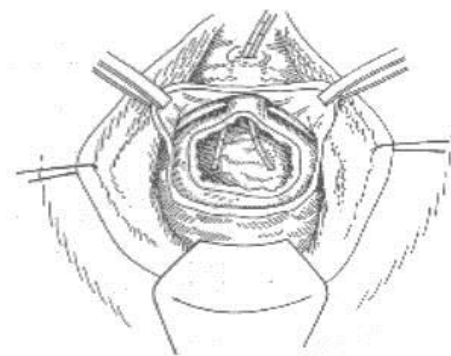


Fig 1:12a: Shows the distal vaginal skin dissected off the bladder/ urethra wall and being held with Allis forceps. (*Les Fistules Obstetricales* by Camey M.)

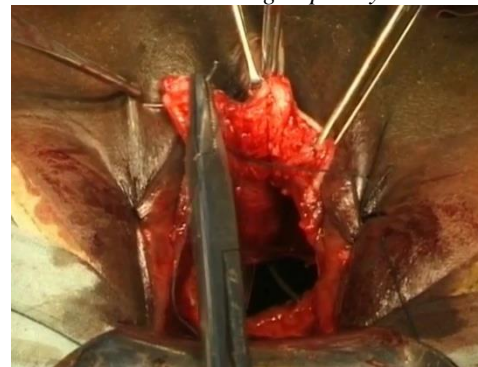



Fig. 1.12b: Shows the distal skin now being stitched back on each side to the perineal skin/ labia majora.

	<p>It is easy to damage the urethra when dissecting distally so not pull hard on the urethra as you dissect as it tears easily. There are several rules to reduce the risk of injury to the urethra:</p>
<ul style="list-style-type: none"> • Put a metal catheter into the urethra to allow you to feel how thick it is by pressing against the metal catheter from outside the urethra with your finger. • Stay close to the vaginal skin rather than the urethra. It may be possible to put your index finger behind the vaginal skin (outer or anterior surface) so that you can cut close to the vagina without making a hole in the urethra. • Between the urethra and the vagina lies the peri-urethral fascia. Often it can be clearly identified as a white sheet under the vaginal skin when entering the correct plane of dissection. Staying superficial to this thin sheet during dissection avoids trauma to the urethra. Bleeding usually indicates you are too deep. 	

PROXIMAL DISSECTION

Nearly all mobilization of the fistula comes from the proximal rather than the distal dissection.

- An assistant holds the proximal bladder edge of the fistula with Allis forceps and the surgeon grasps the vaginal edge with the dissecting forceps (pickups) as you separate the vagina from the bladder using traction and retraction to develop the tissue plane.
- In larger fistulas close to the cervix, as you mobilize proximally with the scissors held vertically, you will reach the harder tissue of the cervix. Instead of dissecting into the cervical tissue, you need to change the

scissors to a more horizontal direction so that you dissect under the bladder to get it off the cervix. A useful tip to do this is to keep the scissors horizontal (parallel to the floor of the operating room) to get into the optimal plane for this. The scissors are inserted between the bladder and the cervix/ uterus.

Note: This is the same step as pushing the bladder up during vaginal hysterectomy.

- Beware of too much blunt dissection during this step as scarring around the fistula can obliterate the normal dissection planes (Fig. 1.13).

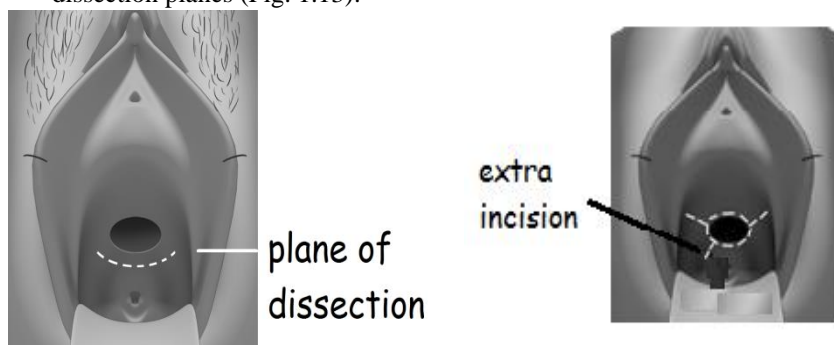



Fig. 1.13: During proximal dissection, finding the correct plane between the bladder and the cervix can be difficult (see text). Remember that the bladder is soft and the cervix is hard.

Fig. 1.14a: Sometimes when dissecting proximally, in difficult cases, a small incision proximally in the vagina will help in mobilizing the vagina and in avoiding the ureter.



Do not start the proximal or lateral dissection until you have identified the position of the ureters. This applies especially in larger fistulas. While waiting to find the ureters may take time, having to re-implant ureters will take longer if you cut them!

! Top Tip! The plane of dissection (and the scissors) changes from perpendicular to horizontal as you come near the cervix. This allows you to go around the corner as you follow under the bladder to mobilize it.

Often the tissues between the bladder and the cervix are fibrosed and the cervix may be damaged. One of the most difficult things to appreciate in fistula surgery is deciding where the bladder ends and the cervix begins especially if they are stuck together. There are a number of useful tips as to where to dissect (see Fig. 1.13):

- The cervix is hard whereas the bladder is soft.
- Estimate the thickness of the bladder wall by looking and feeling through the fistula.
- Estimate how thick the anterior lip of the cervix is likely to be from the distance to the external os. However, the cervix is often split or partially missing anteriorly so be sure to identify the cervical os. It may help to pass a metal catheter or a uterine sound into the cervix and feel how close you are to the cervix.

With this information, make an incision where you think the bladder ends and the cervix begins. If you are in the correct plane, the utero-vesical fold will often open easily. Opening this fold makes the mobilization of the fistula much easier. If the tissue feels hard as you dissect, it is likely that you are too close to the cervix.

LATERAL DISSECTION

The aim of the lateral dissection is to allow the lateral angle of the fistula to come medially so that you can close it without difficulty.

- Dissect about 2-3 cm lateral to the lateral edge of the fistula.
- In large complex fistulas, this means opening the space lateral to the bladder (known as the para-vesical space) on both sides. This is done by:
 - Pulling the bladder medially.
 - Making an incision close to the bone (but not too close to avoid bleeding) of the ischio-pubic rami. This is to avoid making a hole in the bladder. Once made, you then aim to get your finger into the para-vesical (retropubic) space which is recognized by fatty tissue and the muscles laterally (Fig. 1.14b).

If necessary, this dissection can be continued lateral to the urethra by continuing the dissection behind the ischio-pubic ramus to the para-urethral (retropubic) space distally (Fig. 1.14c). This allows the urethra to be mobilized well. This is more likely to be required if the fistula involves the urethra.

! Rule of thumb: The lateral distal dissection is safe, whereas the lateral proximal dissection may injure the ureter or you may encounter bleeding that is difficult to control.

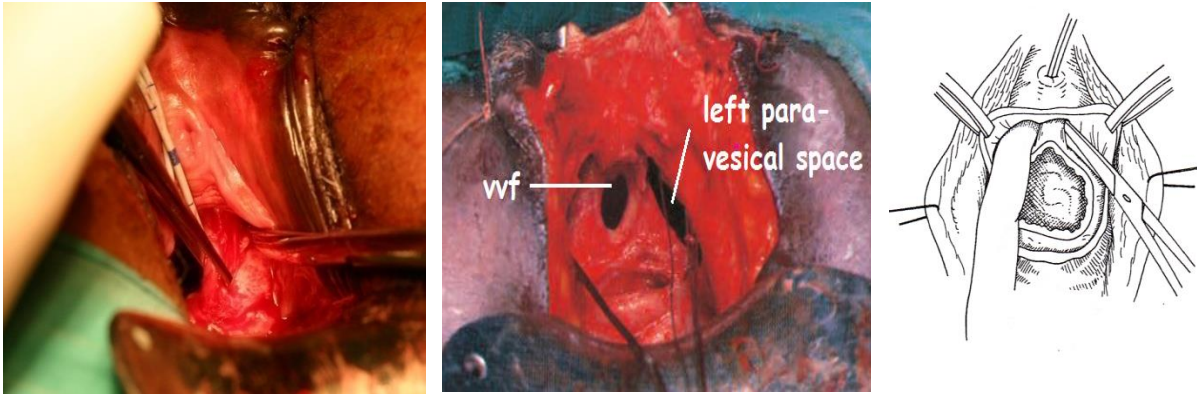


Fig. 1.14b: Shows left the para-vesical space being opened (Courtesy of Brian Hancock).

Fig. 1.14c: Shows the left para-vesical space now open (Courtesy of Kees Waaldijk).

Fig. 1.14d: Shows the dissection being continued distally to the para-urethral space if necessary (from *Les Fistules Obstetricales* by Camey M).

General points on dissection:

- Most of the dissection is performed with curved scissors. The curve of the scissors should be pointing towards the vagina so that it is away from the bladder.
- Once the incision is made, the bladder and vagina are held in opposite directions to create a degree of tension between them i.e. traction and retraction. This reveals adhesions under tension that can be cut to develop the surgical plane.
- Blunt dissection (pushing the bladder up with your finger) can be performed where there is no scarring. Your finger can also locate where scar tissue is so that you know where to cut.
- Blunt dissection by spreading the tips of the scissors is also a very good way of dissecting as this helps to find the correct plane with less bleeding.

! Tip! When dissecting, keep as much tissue on the bladder and urethra as possible i.e. stay close to the vaginal skin.

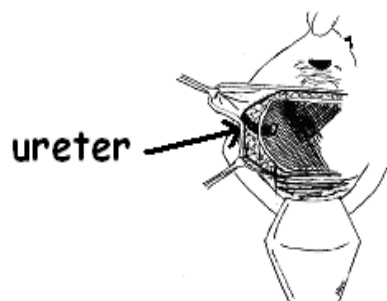


Figure 1.15: Shows the ureter (black) running in the bladder wall. The vagina is being retracted with forceps. The bladder is pulled medially as the vagina is retracted laterally during dissection.

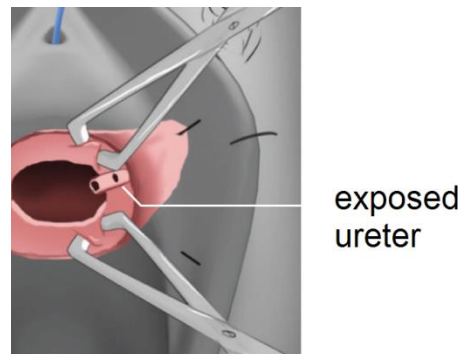



Fig. 1.16: Shows a small hole in the exposed ureter. After repairing the hole in the ureter, it may be possible to get a layer of bladder over the defect to act as a second layer. Hold the bladder on either side (above and below) a bit back from the ureter with Allis forceps as shown. Then suture this part of the bladder over the defect.


PROTECTING THE URETER DURING DISSECTION


Even if you have catheterized them, there is still a risk to the ureters as they run in the bladder wall when dissecting on the lateral and proximal side. To avoid damaging the ureter:

- Palpate for the ureteric catheter as you dissect. Move the ureteric catheter as it enters the ureter to see which path it takes.
- Stay close to the vaginal skin rather than the bladder when dissecting. You need to hold the vaginal edges (especially laterally) with forceps so that you can stay close to the vagina (Fig. 1.15). The forceps on the bladder edges pull the bladder medially (to stretch it) and allow you to see the path the ureteric catheter is taking in the bladder wall.
- In some cases, lateral dissection will be limited because of the ureter's location. You may have to accept this and get mobility elsewhere.

- When dissecting laterally, keep feeling for the ureteric catheter even if the ureter opens more distally into the bladder and seems to be far away.
- Do as much dissection as possible bluntly with scissors by spreading them rather than cutting.
- By leaving the wire in the ureteric catheters, this makes the ureters easier to feel and protects it from being cut completely across (only strong scissors could cut through the wire). This is a very important point.
- Once they leave the bladder wall, the ureters run between the bladder wall and the pubocervical fascia. Therefore you also have to be careful later if you take deep bites of the fascia as this could catch the ureters.
- The course the ureter runs in the bladder wall is usually in a proximal direction but sometimes it is directly lateral as shown in Fig. 1.15. The only sure way of identifying the ureter is to palpate the catheter. Feel the ureteric catheter running in the bladder wall. Then avoid sharp dissection in this area.

 **Tip!** The key to dissection is to stay close to the vagina on all sides. This allows you to stay away from the ureter and for adequate tissue on the bladder to be developed for closure.


 **Top Tip!** If you are about to cut tissue but you are not certain if it contains the ureter, clamp the tissue to be cut and then check if the ureteric catheter is still mobile. If it is mobile, it is not caught in the clamped tissue and this tissue can be safely cut.

	<p>The main blood supply to the bladder is close to the ureters. An important rule in fistula surgery is: It is better to do very little dissection along the ureter to avoid bleeding around the corner of the pelvis, which is very difficult to stop. On one occasion, the only way I was able to stop such (arterial) bleeding was to pack the vagina tightly and suture the pack in with sutures in the labia. The fistula repair had to be completed later.</p>
---	---

IF A URETER IS ACCIDENTALLY OPENED

(a) **If the ureter is partially torn:** i.e. it only tears on one side rather than being completely transected. If a ureter is accidentally opened, or tears during dissection, just re-approximate the torn edges of the ureter with the catheter inside.

- A fine suture of 4/0 or 5/0 should be used to avoid devascularizing the ureter. Use a small (17-22 mm) curved needle or a J-shaped needle as these can get into restricted spaces.
- The main difficulty with closing over the torn part is that the first stitch tends to obscure the view. Therefore, it is better to place 2 to 3 interrupted stitches first before tying them all.
- Once tied, check for any gaps between the stitches. Observe for any urine leaking.
- If possible, cover the repair with bladder – see Fig. 1.16.
- Leave the ureteric catheter in for 14 days if the ureter was repaired.

 **Tip!** When repairing a ureter or when suturing close to it anytime, check after each suture that the ureteric catheter moves very freely. If it does not, it means you are suturing too close to the ureter. Take bites on each side a little further back from the lumen of the ureter. If the catheter moves with difficulty, it is likely that the ureter will obstruct when the catheter is removed.

(b) **If the ureter is completely transected** during dissection: then it is better to re-implant it vaginally (see section 3.4) or abdominally. If performed abdominally, this can be done either:

- Immediately after the VVF is closed: especially if the bladder is of normal size.
- Later when the VVF has healed: especially if the bladder is small. In this case, it is a good idea to catheterize the ureter to avoid it becoming obstructed when the vagina is closed. It is better to use an infant feeding tube which can be transfixed with a suture to the vagina as this is less likely to fall out.

PROBLEMS IN DISSECTION & SPECIAL CIRCUMSTANCES

If the vagina tears: If the vagina is not dissecting easily from the bladder and tears, it usually means you are too close to the vagina. Go a bit closer to the bladder to get into the correct plane.

If the bladder tears, (see Fig. 1.17) it means you are too close to the bladder. To continue dissecting, move the Allis forceps from the edge of the VVF to the torn edge of the bladder to stretch the bladder. Dissect closer to the vagina.

- Hold the edge of the tear with Allis forceps and complete the dissection.
- Usually, it is best to close this injury with the VVF rather than to try to close it separately. Leave the bridge of bladder between the fistula and tear intact and close both together usually in a transverse direction (See step 3).
- If there is a wide distance between the tear and the fistula, you may decide to close them separately.

If there is a narrow bridge of bladder tissue across the fistula (see fig. 1.18a): This is not uncommon with large fistulas. The important point is that the ureters are often at either end of the bridge. Therefore do not cut

the bridge until you have catheterized both ureters. If you have catheterized one but the bridge makes it difficult to find the other one, then cut the bridge close (on the medial side) to the catheterized ureter.

If the utero-vesical peritoneum is opened while mobilizing the bladder: this is more likely if the uterus has been removed, and indeed in this situation may be worth doing as a planned part of the dissection, to improve mobilization. If bowel or omentum comes down through the pouch, a roll of gauze can be inserted to push it back. The pouch can be closed after the bladder is closed or left open i.e. just included in the vaginal closure.

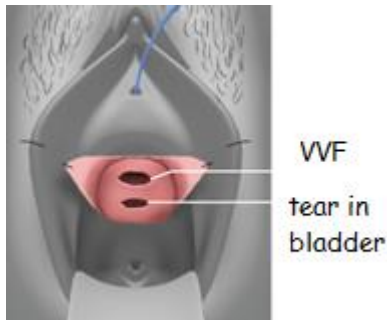


Fig. 1.17: Shows a tear in the bladder proximal to the fistula.

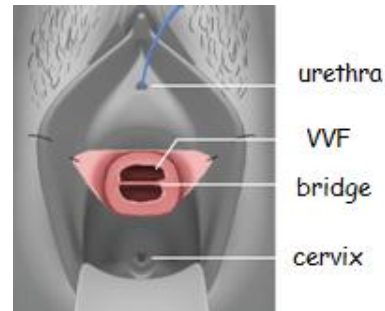


Fig 1.18a: Shows a narrow bridge of tissue in the fistula.

If the fistula is very scarred: Grasp the proximal part of the bladder in the midline and a bit to the sides with Allis forceps. Then look inside the bladder with the metal catheter. If you cannot see the ureters, start the dissection in the midline proximally. Then extend it upwards and laterally through the scar tissue. Stay close to the vaginal skin to avoid the ureters and use as much blunt dissection as possible. If you are outside the fascia of the bladder, the ureter is not likely to be at risk.


TRIMMING THE FISTULA EDGES

This is only performed as little as possible.

- If a small rim of vaginal skin has been left on the fistula edge, trim the edges of the fistula. This can be done with fine scissors. The fistula edges can be held with Allis forceps to stretch the edges. Only a small rim of tissue is removed.
- The bladder edges should be soft. If the edges you are about to close are hard, you may have to excise more scar tissue until you reach bladder tissue. If the edges are already soft, there is no need to excise.

SUMMARY OF DISSECTION

- Distally:** You do not actually get mobility distally but the aim is to expose the urethra/ distal bladder (with the overlying fascia) enough for repair. Mobility is gained by the proximal and lateral dissection. The aim of the distal dissection is only to get enough tissue exposed (the urethra and the distal bladder) so that you can insert the sutures. The urethra and the distal bladder are fairly fixed in this area so you have to get the bladder down to the urethra rather than the urethra to the bladder.
- Proximally:** between bladder and cervix. In larger defects, mobilize the bladder off the cervix. This is the place (besides retropubically for circumferential repairs) that you can gain most mobility.
- Laterally:** open the para-vesical spaces if necessary.

	SECOND CHECKPOINT: BEFORE YOU START CLOSING THE BLADDER
1.	Check that the fistula edges are sufficiently mobile on all sides. The way to do this is to pull the proximal fistula edge with an Allis forceps up to the distal edge to see that they can be approximated easily. If not, then mobilize further.
2.	Can you clearly see the extent of the fistula all around especially the angles of fistula?
3.	Check that the tissue is actually the bladder. Sometimes the tissue near the cervix may be confused with bladder especially if it is stuck to the bladder. Remember the bladder should be soft whereas the cervix is hard. Has scar tissue been excised from the edges?
4.	Are the ureters protected?

STEP 3: CLOSURE OF THE BLADDER

- The bladder should be closed in one layer. Two-layer closure is rarely possible in fistula surgery as it would create too much tension and is usually only possible in simple cases.
- In most cases, the bladder is closed transversely but check which direction will give the least tension (Fig. 1.19a).
- Closure is done with interrupted sutures of 2/0 or 3/0 Vicryl or chromic catgut. A continuous suture line constricts the blood supply more which may result in the breakdown of the repair.
- A suture only adapts tissue but cannot produce healing. Healing occurs in between the sutures.
- You want the mucosa inverted so that it is not visible. This is done by picking up mainly the muscle layer (Fig. 1.18 b+c). Either avoid the mucosa completely or only pick it up at the edge.

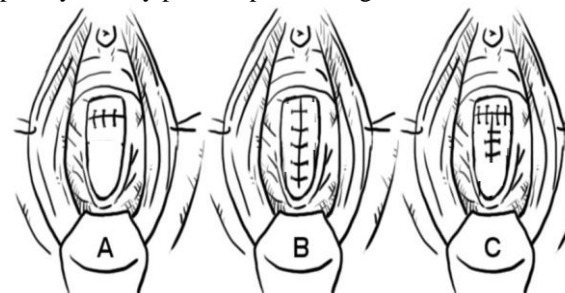
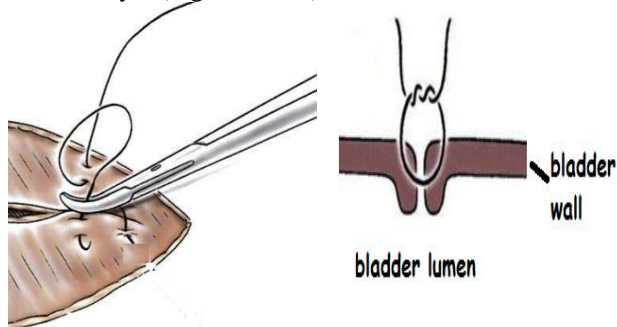


Fig. 1.18b+c: To get the bladder mucosa to invert, bites are taken 1-2 mm back from the edge so that you only pick up the muscle layer. (Courtesy Paul Hilton)

Fig. 1.19a: Closure can be transverse (A), longitudinal (B) or a combination (C). Adapted from *les Fistules Obstetricales* by Camey M.

The following description applies mainly to transverse closure which is the most common method used to close fistulas. **⚠ Top Tip!** If you have a choice, always close transversely as it is more likely to heal well.

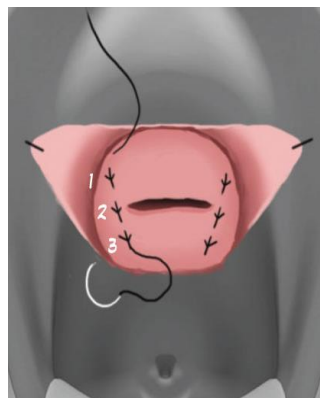


Fig. 1.19b: Showing the closure of the angles in 3 bites numbered 1, 2 and 3.

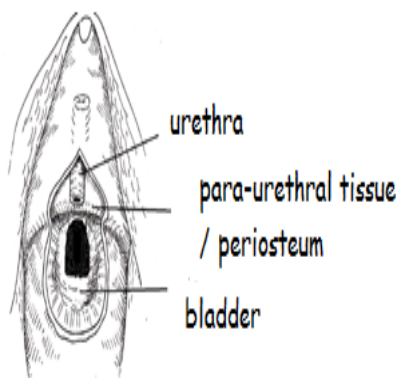
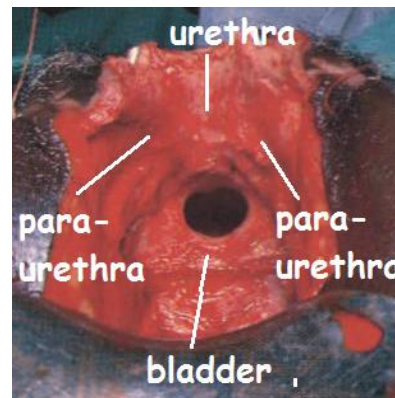


Fig. 1.20 a+b: In many large defects the distal lateral stitches will mainly bite on to the para-urethral tissue and the pubic bone. Only the distal central sutures go through the urethra itself. The proximal ones bite on to the bladder.




ANGLES

- Put in an angle stitch on each side first about 0.5- 1 cm lateral to the fistula edge. To take the angles well, it often helps to do it in three or more bites (Fig. 1.19b). If you only take two bites, when you tie, the area where the central bite should be taken (bite 2 in Fig. 1.19b) will tend to fold in and not close. This is often the cause of the persistent corner fistula.
- When one angle is far out to the side, close that side first as this will be the side that is more likely to leak. It is much easier to put the stitches in carefully initially, rather than trying to get them in later when there is a leak.
- For difficult angles see chapter 2 (Fig. 2.5).
- When closing the left angle, use a backhand grip of the needle with your elbow raised up and laterally. This allows you to place the suture better (see Appendix 2).

- While closing the angles, to avoid catching the ureteric catheters, take one bite above and one bite below the catheter (see Fig. 1.23c). Check the mobility of the catheter after you place the stitch.

! Top Tip! In most cases, before closing the angle, put an Allis forceps on the lateral edge of the proximal bladder and pull medially (see Fig. 1.23a+b). This makes it easier to see the angle. If it is still difficult to see the angle clearly, then you need to do more lateral dissection to allow the angle to come in more medially. Using an Allis forceps in this way is useful for displaying the angles and also the more lateral part of the fistula. Just trying to do this with the pickups/ dissecting forceps is not usually as effective and often leads to gaps in the closure.

	<ul style="list-style-type: none"> • When closing the angles, make sure the ureteric catheters are freely mobile after inserting the first few sutures. It is better to discover this now rather than when the catheter is due for removal. • If the ureteric catheter has been caught by a suture and it is too late to remove the suture, then the catheter will have to be left in place until the suture dissolves i.e. 3-4 weeks post-repair.
---	--

CENTRAL SUTURES

Sutures are placed 3-4 mm apart so that there are no visible gaps between the sutures. Work from the lateral part of the defect towards the centre on each side, alternating right and left.

! Top Tip! As the defect becomes smaller, to help with exposure, stretch the proximal bladder by pushing pickups/ dissecting forceps or a metal catheter into the fistula (see Fig. 1.23d). This makes it easier to insert the needle into the proximal edge of the fistula as it is pushed forward.

- When the bladder closure is complete, if you are not sure if more sutures are required, the suture line can be tested for defects by probing it gently with the closed pickups or metal catheter (between sutures). It is better to find gaps between sutures at this point in the surgery rather than later with the dye test.
- When a fistula is small or juxta-urethral, it may become increasingly difficult to place the sutures as you work towards the centre. In this case, it may help to place all the central (2-3) sutures before tying them.

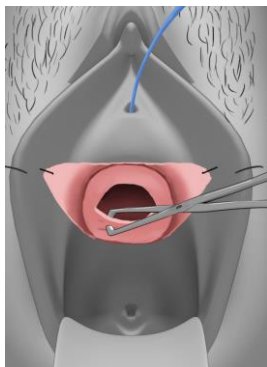


Fig. 1.23a: This shows the bladder edge being pulled medially to show the proximal fistula margin clearly.

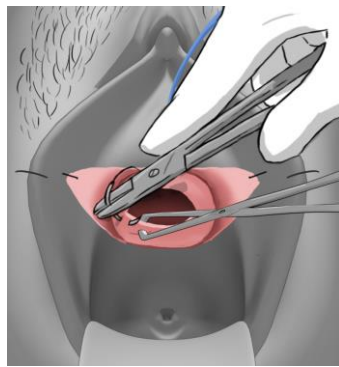


Fig. 1.23b: Once the angle and lateral edge are clearly shown, the suture can be inserted more securely.

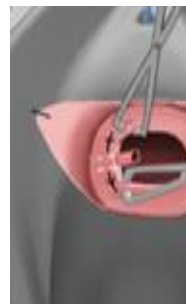

Fig 1.23c: Shows the sutures being inserted to avoid catching the ureteric catheters.

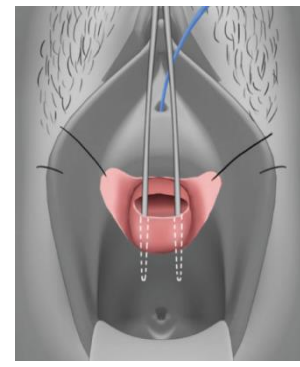


Fig. 1.23d: The pickups are used to stretch the proximal bladder.

! Tip! As you are closing a fistula, it is sometimes difficult to see the remaining part of the defect especially as you get to the central part of the fistula. Use the metal catheter to find it either by (a) inserting it via the urethra and then out through the fistula or (b) directly into the area where you think the fistula should be. Using a thin metal catheter in this way is a great way of deciding where to place your next suture. Alternatively, you can use a fine pickups/ dissecting forceps.

! Top Tip! It is a good idea to insert the Foley catheter before the first layer of the bladder is completed in case you have difficulty inserting the catheter in later. This is especially important for fistulas involving the bladder neck/ urethra. To avoid the risk of catching the Foley catheter with a suture, place the last 3-4 stitches with the metal catheter in place but do not tie the sutures. Then remove the metal catheter and insert the Foley catheter. Only tie the sutures after the Foley catheter is inserted.

- Use 16F if possible but 14F or very occasionally 12F may be used (usually for urethral repairs) if there is any difficulty with 16F.
- Using an 18F is okay when the fistula does not involve the urethra. Large catheters may irritate the urethra but are less likely to get blocked. Clots can only be flushed out with size 16-20F.

Summary of tips for displaying the proximal fistula margin:



The distal part of the fistula is usually easy to see. You must make sure that you can see the proximal part clearly to avoid missing part of the bladder wall. This is critical to getting good success rates with your closures.

- *At the angles and the lateral part of the fistula:* Use an Allis forceps on the proximal edge and pull medially as in Fig. 1.23a + b.
- *Central part of the fistula:* Use pickups or metal catheter inserted into the fistula to push the bladder edge forward as in Fig. 1.23d. When the defect is very small, the metal catheter can be used from inside the bladder to push the proximal bladder forward.
- *All sites:* Once the distal suture bite is placed, get your assistant to retract the suture upwards to show the proximal edge of the fistula. This allows you to place a good proximal bite.

LARGE DEFECTS

An important concept to grasp for dealing with large fistulas is that:

- The distal lateral bites are taken through the para-urethral tissue and periosteum (Fig. 1.20a + b). Only the central 2-3 distal bites can go through the actual urethral wall/ pubo-urethral fascia which is relatively weak and at risk of tearing.
- The proximal bites are taken in the bladder. This means you are closing the lateral part of the bladder to the para-urethral tissue (and bone) rather than the urethra.
- Also, there is often a discrepancy in size between a narrower distal end and a wider proximal end. If the discrepancy is not severe, then the distal bites are taken vertically while the proximal bites are taken horizontally (see Fig. 1.20c). For major discrepancy, see section 2.4.

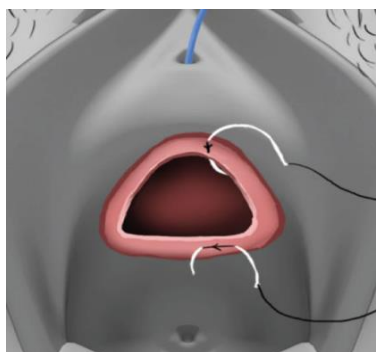


Fig. 1.20c: Shows the distal bites being taken vertically and the proximal bites being taken horizontally.

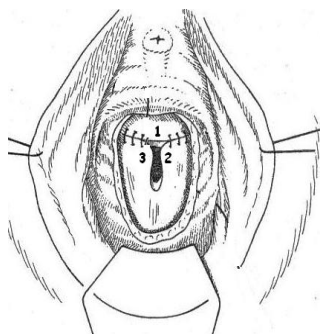


Fig. 1.20d: Shows a T-junction being closed with a triangular stitch.

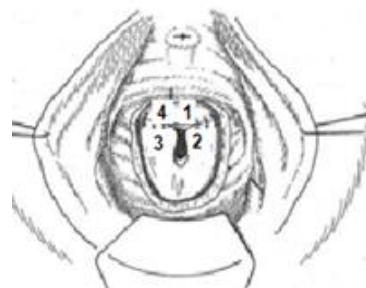


Fig. 1.20e: Shows a T-junction being closed with a mattress stitch.

FORMATION OF A T- JUNCTION

If when you are attempting a transverse closure, you find that there is too much tissue proximally, you can close the central part vertically as shown in Fig. 1.20 d and e. The T-junction (of the transverse and the longitudinal closure) is a potential point of weakness and must be closed with care. To avoid problems:

- Make sure to come up on the vertical closure as distal as possible so the gap between the urethra and the bladder is very short.
- To join the urethra and the bladder, either:
 - Use a triangular stitch taking bites at points 1, 2 and 3 and then tie the suture (Fig. 1.20d). To reinforce this area, a second more superficial triangular stitch can be repeated at points 1, 2 and 3. See also Fig. 2.20c (in chapter 2) for an alternative way of placing this stitch.
 - Or a mattress suture with four bites can be placed as in Fig. 1.20e.

LONGITUDINAL CLOSURE (See Fig.1.21 and 1.22)

When the defect does not come together easily transversely, check if it will come together longitudinally. When stitching longitudinally, it is more difficult to see gaps between sutures. To avoid this:

- Leave the short ends of the suture on an artery forceps so that you can check for any gaps in between sutures.
- Use the metal catheter to probe for gaps along the line as you close the incision.
- Put in the proximal angle stitch first, followed by the distal angle stitch.
- If there is a layer of pubo-cervical tissue laterally on either side, this can be included in the bites while closing the bladder or used as a second layer. Alternatively, some surgeons only close the fascia over the bladder without closing the bladder separately, especially for small fistulas (see also section 3.1).
- When closing longitudinally, it is usually best to take the angles in three bites i.e. the first bite is taken laterally, the second bite is across the fistula angle and then the third bite is taken laterally on the opposite side. To invert the mucosa as you tie the proximal suture, place an Allis or two dissecting forceps on the angle to push in the mucosa as shown in Fig 1.21.

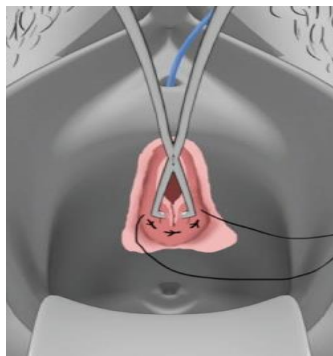
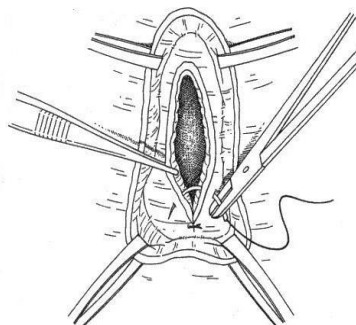


Fig 1.21: Shows the angle suture being inserted.



*Fig. 1.22: Once the angle suture is inserted, continue distally with interrupted sutures. Note the use of the backhand grip when inserting from left to right (from *les Fistules Obstetricales* by *Camey M*).*

FOLEY CATHETER

If there is difficulty inserting the Foley catheter: try the following steps:

- (A) Use a small probe inserted into the tip of the catheter to act as an introducer. Once the catheter is in the bladder, inflate the balloon before you remove the introducer so that the catheter does not come out as you pull out the introducer. The only problem with inflating the balloon before you have finished closing the bladder is that you may puncture the balloon as you insert the final stitches. Therefore advance the catheter well into the bladder and be careful with the stitches.

CAUTION! When the bladder is small, if you have difficulty inserting the catheter, you may perforate through the bladder and cause a new hole if you are not careful. Do not go in too far with the probe.


- (B) Consider removing the last few sutures inserted until the catheter can go in easily.

- (C) If you still have difficulty, it is best to insert a size 14F Foley or place a Nelaton catheter (see Appendix 5).

Tip! Anytime you are repairing a fistula that involves the urethra, if you have trouble inserting sutures without catching the Foley catheter: Place all the central sutures with the metal catheter in place but only tie them after inserting the Foley catheter.

If you catch the Foley catheter with a suture: and you recognise this during the operation but it is too late to undo the suture(s), slide thin sharp scissors along the Foley until you find the suture and cut it. Replace the Foley as it leaks from the hole and sometimes you will have punctured the channel for the balloon.

If this is not possible and removing sutures would increase the risk of failure of the repair, leave in the catheter longer than usual to allow time for the sutures to dissolve.

	<p>Make sure the balloon of the catheter is fully in the bladder before allowing your assistant to inflate it. A common mistake is for the assistant to pull on the catheter as he inflates the balloon. This can result in the balloon being inflated in the urethra which can lead to tearing of the urethra.</p>
---	---

Tip! If you have trouble inserting the Foley catheter, it may help to use the hole in the almost-closed fistula to assist the catheter going in with a non-toothed dissecting forceps.

Tip! Always inflate the balloon of the Foley catheter immediately after inserting it before doing the dye test. Otherwise, the catheter may come out during the dye test. It is sufficient to inflate with 5-10 mls.

DYE TEST

Check that the repair is water-tight at the end of the bladder closure. Make it a routine to empty the bladder before you do the dye test in case the bladder is already full. There are different methods of injecting dye (diluted methylene blue or gentian violet) via the Foley catheter: the push, gravity and pressure methods.

The push method: The common method in the past has been to inject 60 ml of dye and exert gentle pressure suprapubically or get the patient to cough. You may have to block the urethra with digital pressure (see Fig. 1.24e) when doing this especially if a lot of the dye leaks out through the urethra, as otherwise you may miss a leak. The problems with the push method are:

- If the bladder is small, even 60 ml of dye may be too much. With high pressure, the repair will start leaking everywhere even if it is adequate.
- The problem with supra-pubic pressure or getting the patient to cough during the dye test is that these may increase the intra-vesical pressure by 100 cm H₂O or more, and these are more likely to cause stress leakage from the urethra. Because of the problems with the push method, the following methods are preferred.

(a) **If you suspect a small bladder or you are not sure of the size: use the gravity method** (see Fig. 1.24 f + g):

- Using only the barrel of the syringe, attach it to the Foley catheter.
- Then pinch the Foley catheter as you fill the syringe so that you can measure the amount that goes into the syringe.
- Hold the syringe barrel about 20 cm above the urethral level and let the dye flow in by gravity.
- Continue to fill the syringe until dye no longer flows.

The advantages of this method are:

- Up to 180 ml of dye (depending on the bladder capacity) will lead to only a few centimetres H₂O pressure rise.
- It is especially useful if the bladder is small.
- It gives an estimate of the bladder capacity which is useful if the patient has incontinence later.

(b) **If you think the bladder is a reasonable size: use the pressure method:** this is a faster method especially if the bladder is of normal size. The aim is to fill the bladder until the pressure within the bladder is 10 cm H₂O.

- The syringe end of the catheter is held vertically 10 cm above the urethra (see Fig. 1.24h) without the barrel of the syringe attached.
- Only attach the syringe to the catheter when injecting a syringe with dye and then remove the syringe.
- Check the pressure after every 30 ml of dye. When you see the dye rising up and leaking out the Foley, then the pressure has reached 10 cm (see Fig. 1.24h).
- Measure the volume in the bladder at the end by emptying the dye into a container.

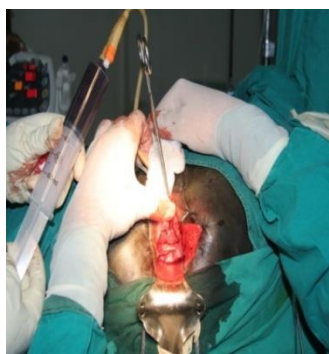

Fig. 1.24e: Shows the push dye test. Note the urethra is being compressed to prevent leakage.

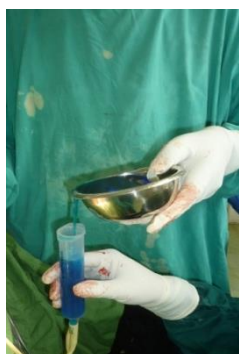

Fig. 1.24 f and Fig. 1.24g: Show how to do a gravity dye test.

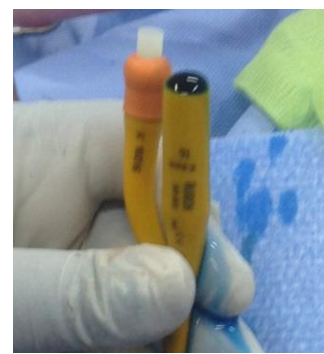
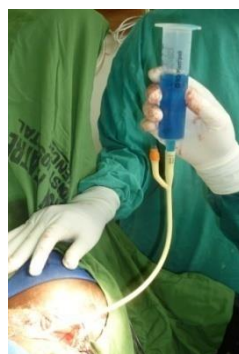
Fig. 1.24h: Shows the pressure dye test with the dye spilling out of the Foley catheter.

If the dye test is positive: there is a natural disappointment and a sense of failure. However, do not make the situation worse by rushing to correct it. Try to insert a small metal catheter into the defect. Then apply Allis forceps to identify the leaking area clearly. See how big the defect is.

- If the defect is small and can be clearly seen, 1-2 more sutures are applied to the leaking area. It often helps to mobilize the intermediate layer/ pubo-cervical fascia (see below) and use this as part of the closure.
- If the defect is larger than a metal catheter, you probably have an unrecognized gap in the bladder closure.

It is probably better to undo the repair on the affected side and start again.

If there is only a tiny leak: especially if it occurs when the bladder is full, it is likely that the bladder will heal with free drainage. On one occasion after doing a difficult repair, there was a tiny leak high up. Rather than redoing the repair, we just relied on the free drainage and the fistula healed.

If the dye test remains positive:

- If the dye leaks and it is not possible to put more sutures in the first layer, build up the intermediate layer (see below) and repeat the dye test. This usually means applying a patch of pubo-coccygeus or a Gracilis flap over the area and stitch it in place.
- If the angle is leaking and you have closed it well, it would not be a good idea to undo the repair. In this situation, sew the bladder to the pelvic side-wall over the leak and then maybe even add a muscle patch over it. For example, if there is a leak at 2 o'clock (on the left), stitch the bladder to the pelvic side wall muscles from about 1 o'clock to about 6 o'clock. Try to suture as close to the defect as possible to close the defect as tightly as possible and not to make any tracks under the sutures from the fistula to the outside. Use interrupted stitches to do this. Surprisingly this method sometimes works. (See also section 5.3b if you have failed to close the angle securely.)

STEP 4: INTERMEDIATE LAYER

- The main purpose of an intermediate layer is to reduce the risk of failed repair by acting as:
 - a. A mechanical barrier by separating the bladder/ urethra from the vagina or uterus.
 - b. A source of perfusion of previously poorly vascularized tissue. Therefore the intermediate layer should preferably be vascular and easily mobilized with its blood supply.
- In addition, in any VVF there is anatomic tissue loss of the endopelvic musculo-fascia as well as the bladder/ vagina defect. Therefore one should make an effort to identify the musculo-fascia defects and repair them together with the fistula. This will help restore continence.

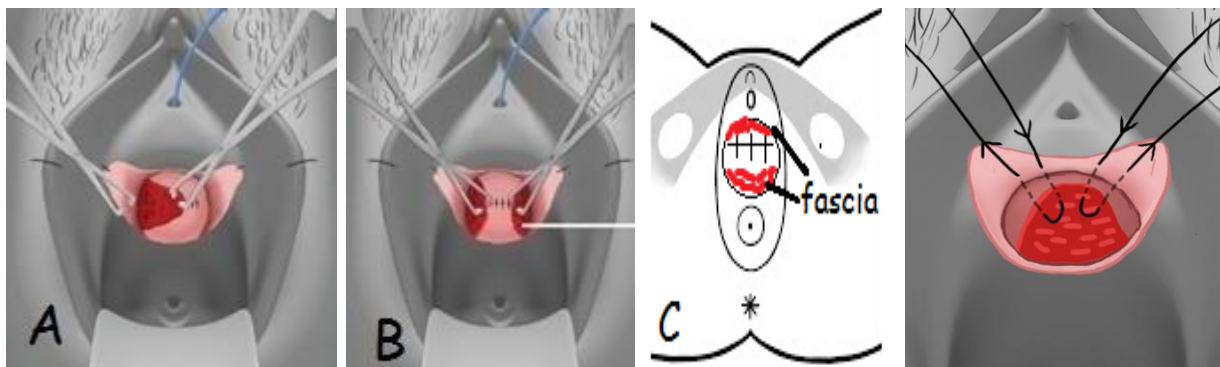


Fig. 1.25: A: An Allis forceps is applied to the pubo-cervical fascia which is pulled medially while a second Allis is applied to the vagina which is pulled laterally.

Fig. 1.25B: Once mobilized, stitch the fascia of each side across the midline to cover over the VVF repair. Several sutures may be required.

Fig. 1.25C: In some cases, the fascia/ smooth muscle (in red) may be approximated transversely by suturing the distal tissue over the urethra and para-urethral tissue to the proximal tissue which is found between the bladder and vagina in front of the cervix. In Fig. 1.25D this layer is re-attached directly to the bone.

For healing of the fistula, an interposition layer is not usually needed if the bladder tissues appear well vascularized. While there is no high-level evidence to confirm the benefit of placing an interposition layer, most fistula surgeons would use tissue interposition in selected cases:

- a. Those that have failed previous repairs especially if scarred or multiple repairs
- b. Fistulas post-radiotherapy
- c. A fistula associated with a difficult or tenuous closure because of poor tissue quality i.e. the bladder is thin or friable or if there is difficulty getting the dye test negative.
- d. Distal fistulas do not heal as well as proximal ones. Therefore for juxta-urethral and fistulas involving the urethra, it is a good idea to place an intermediate layer. In these, it may also reduce the risk of stress incontinence.

There are several options:

- (1) **Pubo-cervical fascia:** This layer lies between the bladder and the vagina. Do not look just for fascia but for smooth muscle since that is the main component of this layer. In smaller fistulas, where there is not too much tissue damage, often this layer can be developed on each side as you dissect laterally (see Fig. 1.25a,b,c).

- (2) **Bulbocavernosus muscle/ Para-urethral tissue:** this is useful for fistulas of the urethra as it is found just lateral to the urethra, superficially under the skin. By mobilizing it on both sides, a sling can be formed across the urethra. The tissue does not resemble muscle but is more like fascia.

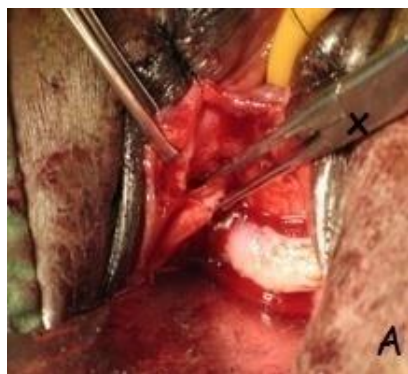


Fig. 1.27a: Shows the pubo-coccygeus muscle being grasped with an Allis forceps marked X.

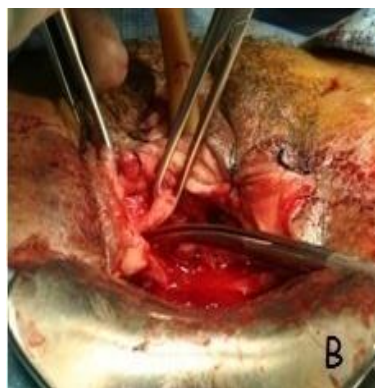


Fig 1.27b: Shows the muscle being freed proximally by cutting sharply with scissors.

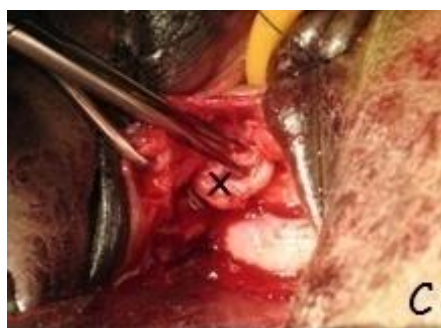

Fig. 1.27c: Shows the freed muscle (marked X).

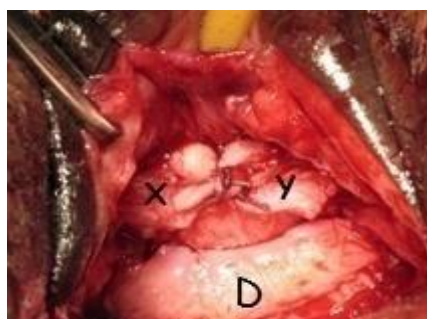


Fig. 1.27d: Shows the muscle (X) sutured to the one (Y) from the opposite side.

- (3) **Pubo-coccygeal muscle:** This is the medial part of the levator ani so it is quite deep (below the bone of the ischio-pubic ramus as you look vaginally) and found in the lateral pelvic wall. It is deeper than the pubo-cervical fascia. It is particularly good for juxta-urethral fistulas. There are two main uses of it:
- If mobilized on both sides, this tissue can be sutured together in the midline across the urethra to form a sling (Fig. 1.26b). The aim is to reduce the risk of stress incontinence although this is not proven. There is only weak evidence from one study where stress incontinence reduced from 33% to 18% after the introduction of the sling. *Reference: Browning A: Prevention of residual urinary incontinence following successful repair of obstetric vesico-vaginal fistula using a fibro-muscular sling: BJOG April 2004, Vol. 111, pp. 357–361.*
 - If mobilized from one or both sides, it can be applied as a patch or intermediate layer over a fistula. It is particularly good for covering repeat corner repairs (see section 3.8). See Fig. 1.27a-d.
- (a) You often need to dissect more of the vaginal skin off the lateral wall posteriorly to expose the muscle i.e. it is the lower flap of the lateral extension that needs to be freed more. The line of muscle is deep to and in the line of the lateral extension.
- (b) Start proximally and apply an Allis forceps to the muscle to pull medially as you dissect out the tissue. Free the upper border of the muscle bluntly by pushing in and opening scissors.
- (c) Then cut with scissors to free the muscle flap proximally. Initially just cut in a transverse direction (Fig. 1.26a) into the muscle.
- (d) Once the proximal part is free, then cut laterally so that you end up with a 1-2 cm wide cylinder of muscle. The trick is to pull on the Allis as you are cutting. You should end up with a flap on each side which has its base distally at about 2 o'clock on the left or 10 o'clock on the right as shown in Fig. 1.26b. Do not go too deep or cut too close to the bone as this increases the risk of bleeding. If cautery is available, this can be helpful both for developing the pedicle and haemostasis. See that the tissue comes to the midline without tension on each side before any stitching. If it does not, mobilize it more.

! Tip! When stitching either the pubo-cervical fascia or the pubo-coccygeus: start the suture from the mid-line and take a bite of the right side. Then starting again from the mid-line, take a bite of the left side. The reason for doing this is that when you tie this suture, it is less likely to pull through the tissues as both sides pull towards the centre (known popularly as the baseball stitch).

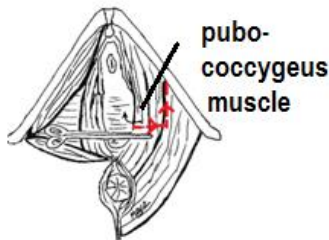


Fig. 1.26a: Shows the anatomy and direction of cutting (red arrows) the pubococcygeus muscle which is about to be cut proximally.

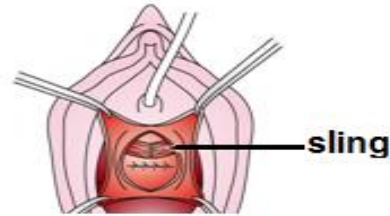


Fig. 1.26b: Once a strip of muscle is freed on each side, it can be tied across the midline.

- (4) **Martius graft/ flap:** Where there is no tissue to form an intermediate layer, a Martius graft can be performed in some cases especially for fistulas involving the urethra (see section 8.4).
- (5) **Gracilis flap:** Because of its size and vascularity, this is an excellent flap which is occasionally used in difficult repairs (see section 8.5) i.e. repairs that have a high risk of failure.
- (6) **Peritoneal flap:** This can be used in a vault or any high fistula. It is brought distally to cover the fistula suture line, and attached to the distal bladder wall or periosteum. Either:
 - If the pouch of Douglas is opened, then a flap of peritoneum can sometimes be brought down. When available, this is a safe option as there is no risk of injuring the bladder.
 - The peritoneum may be dissected without opening the pouch. One of the dangers of this is that you may dissect into the bladder wall.
- (7) **Omentum:** This can be used occasionally if it presents itself when either the anterior or posterior pouch is opened.



THIRD CHECK POINT: BEFORE STARTING TO CLOSE THE VAGINA

i.e. before you cut the stay sutures that retract the distal vagina, ask yourself if there is anything you are forgetting? Have you done the dye test? Is the Foley balloon inflated? Did you need to place an intermediate layer? Does the cervix need repairing?

STEP 5: CLOSURE OF THE VAGINA

- While stitching the vagina, it often helps to replace the weighted speculum with a smaller Sims speculum.
- The proximal vaginal edges may be difficult to see and are held with Allis forceps once found.
- A large needle (36 mm) is useful in getting deep, haemostatic bites of tissue.
- If there is difficulty closing the vagina due to skin loss, see section 8.1.

If the vagina is friable and cannot hold the stitches: Remember to use a large needle. Chromic catgut is less likely than Vicryl to cut through the tissues.

- Distally: insert the stitch as distal as possible, if necessary starting almost outside the vagina to get a good bite of skin.
- Proximally: go deep also and if necessary go close to the cervix.
- To close the dead space, it helps to take bites of the fascia underneath the vagina as you stitch the vagina.

When the VVF was large and there were large lateral extensions made in the vagina, you need to use a slightly different technique to close it (Fig. 1.28 b + c). Do not start at the most lateral point of the vaginal opening. Instead, place the first stitch at about 10-11 o'clock on the left and 1-2 o'clock on the right. These bites should close the angles of the original (vaginal part of the) fistula rather than the lateral extensions. If you placed the very lateral sutures first, they would obscure your view of the more medial vagina. Most of the bleeding tends to be from the more medial aspect so it is important to secure this first. An optional extra when closing the vagina in cases of juxta-urethral fistulas, on each side, having taken the distal bite (1 in Fig. 1.28d) through the vagina, take a bite (2 in Fig. 1.28d) of the periosteum at 11 or 1 o'clock. Then take the proximal vaginal bite (3 in Fig.

1.28d) and tie. The purpose of this stitch is to prevent the vagina pulling the urethral orifice open. Only one of these sutures is placed on each side.

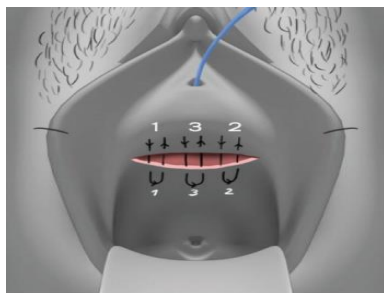


Fig. 1.28a: Shows closure of the vagina with interrupted mattress sutures. In most cases, the vagina can be closed transversely by a series of interrupted (vertical) mattress sutures.

- Close each angle (1 and 2 as shown) first, and then the more central sutures (3).
- Start distally and go proximally with deep bites. Therefore start 2 cm back from the edges. Taking deep bites helps to close any dead space.
- Then come back up closer to the edges and tie as shown.

If the vaginal opening is large:

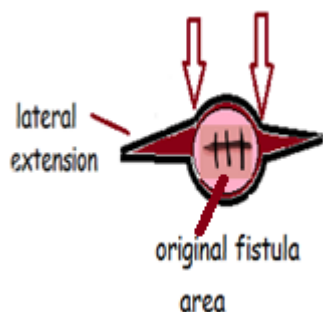


Fig. 1.28b: This is a diagrammatic representation of the open vagina. The arrows represent where you place the initial sutures.

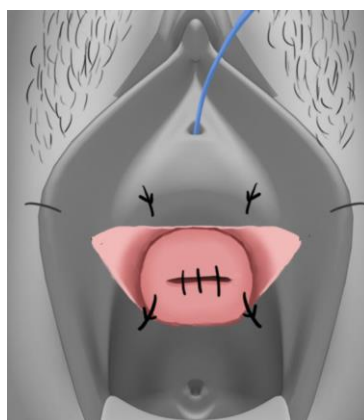


Fig. 1.28c: Shows the placement of sutures where vaginal closure should begin.

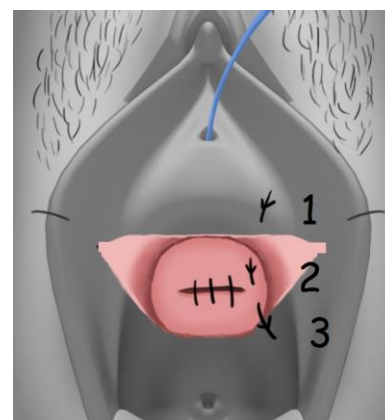


Fig. 1.28d: Shows the vagina being closed with a suture that incorporates the periosteum at 1 o'clock.

WHAT CAN YOU DO DURING THE OPERATION TO REDUCE THE RISK OF STRESS INCONTINENCE?

- Intermediate layer:** In all cases of Goh 3 + 4 or Waaldijk Type 2 fistulas, look for defects within the pubo-cervical fascia/ smooth muscle and its attachment to the pubic bones. Then repair them carefully.
- Fascial sling:** This can only be placed at the time of repair if no tension is applied to the sling, otherwise it is likely to interfere with healing of the fistula.
- Vagina:** When closing the vagina in fistulas that involve the urethra: If there is a deficiency of skin, it is important that there is no pull on the urethral opening.
 - If the vagina can be approximated without tension, insert the suture as shown in Fig. 1.28d.
 - Consider using a skin flap to close the anterior vagina (section 8.1) if the two sides of the vagina are widely separated. It is better not to forcibly approximate them, as otherwise the scarred tissue will pull open the posterior urethral wall. This tethering effect may keep the urethra constantly open even at rest. In trying to decide whether to do a flap or not, during vaginal closure it helps to assess: (a) Is the urethra being pulled open? (b) Is the cervix being pulled anterior? (c) Is there tension when closing? If the answer is yes to any of these, then a flap should be considered.
 - To further reduce the risk of stress incontinence with a Singapore flap, a suture can be placed through the fascia of the flap to the rectus sheath – see Singapore sling chapter 8.

STEP 6: LAST STEPS + SUMMARY

(1) VAGINAL PACK: Good packing is important to reduce the risk of bleeding and hematoma formation. If proper packs are not available:

- Stitch several gauze swabs together with one bite of a suture and tie this. The number of swabs will depend on the size of the vagina. Avoid any unattached swabs which can easily be left in the vagina.
- Use an abdominal swab which can be cut if necessary.

Always leave a piece of swab protruding out of the vagina to avoid patient discomfort when removing the swab.

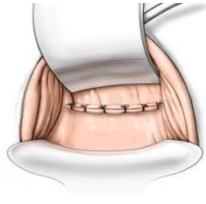



Fig. 1.29: Shows a retractor in place.

- A speculum should be inserted anteriorly to protect the suture line as you insert the pack (Fig. 1.29).
- If there are some areas of the vagina where it was not possible to get complete closure, then use Vaseline gauze tied to the start of the pack for the initial packing to avoid the pack sticking to the raw areas.
- In cases where you are concerned about post-operative bleeding, the pack may be sutured in place to increase its effectiveness. Place 2-3 deep transverse sutures into the labia majora on each side. This will keep pressure on the pack in the vagina.

	<p>The most common reason for bringing a patient back to the operating room is bleeding from the vaginal edges. Before you pack, swab the vagina to check that all bleeding has stopped. If there is still any oozing, insert more sutures until the vagina is dry. Do not rely on a pack to stop bleeding.</p>
---	---

(2) **FOLEY CATHETER:** Most surgeons prefer to tape it to the supra-pubic region to avoid any tension on it so there is no pull on the balloon and the repair. It helps to place a layer of adhesive strapping on the skin under the catheter, then lay the catheter down and put a second layer over the catheter.

Tip! It is a good idea to leave a gap or “mesentery” of tape between the skin of the abdominal wall and the catheter (Fig. 1.30a). This helps avoid kinking of the catheter. It also secures the catheter better as the tape goes around the whole circumference of the catheter. Some surgeons tape the Foley to the leg but this will lead to pulling on the catheter as she walks.

Tip! In addition to strapping, if a fistula involves the urethra, it is a good idea to fix the Foley catheter with a suture to the skin suprapubically.

(3) **URETERIC CATHETERS:** During the operation, make sure these are fixed securely with sutures to the suprapubic skin. It can be disastrous if these come out prematurely. In addition, at the end of the operation, secure them to the Foley catheter with three ties around the ureteric and Foley as in Fig. 1.30b.

Most ureteric catheters come with a connection piece that allows:

- An infusion set to be connected using the cannula end (of the infusion set). The other end of the infusion set can be put into a bucket (after the drip chamber has been cut off and the roller clamp removed) or an empty bottle/ infusion bag.
- The barrel of a 2-5 ml syringe to be connected. The end of a urine bag can then be inserted into this.
- Use the same tubing which connects to the Foley catheter but cut the tip off it. By dilating the tubing slightly, it will usually connect to the connection piece.
- Special connecting tubings for ureteric catheters are available (Angiotech Ref: 404017030).

Do not pass the ureteric catheters into the Foley by making a small opening just above where it is joined to the collecting tubing. This inevitably leads to leaking.

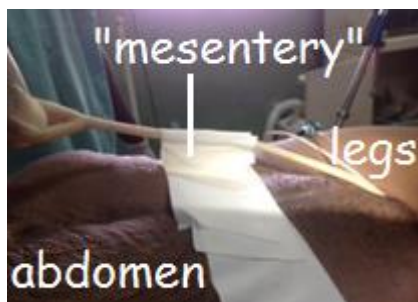


Fig. 1.30a: Shows the catheter taped suprapubically. Note the “mesentery” with a gap between the catheter and the skin.

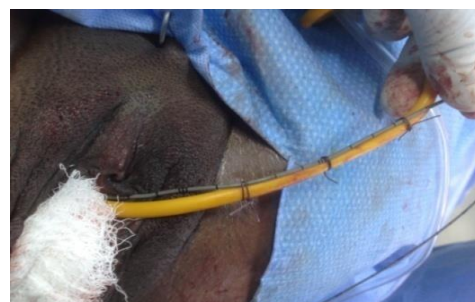

Fig. 1.30b: Ureteric catheters tied to the Foley catheter at three points..

FINAL CHECKS

The good work of the operation can be undone if you do not check the following before the patient leaves the operating table.


- Is the Foley catheter properly secured and was the balloon inflated?
- Are the ureteric catheters secured? This will avoid a lot of problems later so take time to do it properly.
- Always check that urine is draining from all catheters immediately after surgery before you leave the patient. If no urine is draining: (a) Inject 10 ml saline into Foley catheter: if this does not come back freely

when you inject, suspect that the catheter is not in the correct place i.e. not in the bladder. Recheck. (b) If the flush test is okay, increase the intravenous fluids until flow is seen. Do not hesitate to give Frusemide IV.

BLEEDING DURING FISTULA SURGERY

With large fistulas, excessive bleeding during surgery is a common problem (especially if they are soft and not scarred), and it can be easy to ignore it as you are focused on closing the fistula. As blood supplies are limited in most settings, you have to take steps to reduce or stop the bleeding.

Venous bleeding is the most common type. If you cannot easily suture the bleeding area, try the following: Pack the lateral para-vesical spaces or any bleeding areas with part of a vaginal pack or small gauze swabs but take note of how many you have inserted as it would be easy to leave them behind. You can usually continue operating while these are in place. Soak the pack with diluted adrenaline (same concentration as for infiltration). You may have to accept blood loss that will only stop when you close the vagina. It is better to operate a bit faster than waste time trying to clamp bleeders that are difficult to catch.

	If bleeding increases during the operation, always look carefully for an arterial bleeder which may be hidden behind a flap of vagina. Do not assume that the bleeding is venous and that it will stop when you close the vagina.
---	---

Arterial bleeding: If it occurs apply artery forceps or, if the bleeder is a long way in, use long artery forceps. Then suture the bleeder. Alternative options to deal with the bleeder are:

- Cauterize the artery or just leave an artery forceps on for 10 minutes. This is sufficient for small arteries. If it is a large artery, suture it at once. If you fail to stop the bleeding, leave the clamp on for 30 minutes before you try again to stitch it. It may be possible to continue with the repair in the meantime.
- Deep figure of eight sutures are useful laterally (near the ureters) if you cannot clamp the bleeder. If you apply a figure of 8 suture for bleeding, leave the ends a bit long in case there is recurrent bleeding.
- Pack with Surgicel ® or apply Floseal ®. If all else fails, you would have to pack the vagina very tightly and stitch in the pack by stitching the labia together.

SUMMARY OF KEY STEPS	SAFETY CHECKS
(1) Expose and inject vasoconstrictor. Rule out stones and ensure only one fistula.	Check for ureters and catheterize.
(2) Incise and dissect vagina off to expose pubo-cervical fascia and bladder. Do distal, proximal and lateral dissection. Excise all scarred tissue around the fistula.	Protect ureters during dissection.
(3) Close bladder (tension-free) starting at each angle. Then place the lateral and central sutures interrupted every 3-4 mm.	Protect ureters. Pass Foley catheter and do dye test.
(4) Intermediate layer if indicated.	
(5) Close vagina and pack.	Check haemostasis.

SUMMARY OF WHAT THE SURGEON’S HANDS ARE DOING DURING VVF REPAIR		
	<i>Left-hand</i>	<i>Right-hand</i>
(1) Vaginal incision	Steady vagina with dissecting forceps.	Holds knife as you incise.
(2) Dissecting vagina off bladder	Holds vaginal edges with dissecting forceps. Your assistant holds the bladder or vagina up with Allis.	Holds scissors as you dissect.
(3) As you look for the ureters	Holds a metal catheter to stretch bladder wall inside.	Holds a suction tip.
(4) As you trim the bladder edges	Holds the bladder edge with dissecting forceps.	Holds scissors.
(5) Closing bladder	(a) <i>Distal bladder/ urethra:</i> steadies it with dissecting forceps. (b) <i>Proximal bladder:</i> Holds the bladder edge with dissecting forceps or Allis.	Holds the needle holder.